
REVIEW

Calcium hydroxide pastes: classification and clinical indications

L. R. G. Fava¹ & W. P. Saunders²

1 Endodontic Practice, São Paulo, Brazil, and 2 Adult Dental Care Education Group, University of Glasgow Dental School, Glasgow, UK

Abstract

Fava LRG, Saunders WP. Calcium hydroxide pastes: classification and clinical indications (Review). *International Endodontic Journal*, 32, 257–282, 1999.

Review article Calcium hydroxide has been used in endodontology for many years. The aim of this paper is to review the various formulations of calcium hydroxide that have been described, with specific reference to the vehicle used to carry the compound. The requirements for a vehicle are described, and *ex vivo* and *in vivo* studies

reviewed. Vehicles can be classified into aqueous, viscous and oily, the clinical properties of calcium hydroxide changing depending on the vehicle. The review also describes the use of various active components that have been added to calcium hydroxide, including antimicrobial and anti-inflammatory agents. This review will help clinicians to make informed judgements about which formulations of calcium hydroxide should be used for specific endodontic procedures.

Keywords: calcium hydroxide, pastes, vehicles.

Introduction

Since the introduction to dentistry of calcium hydroxide by Hermann (1920, 1930), this medication has been indicated to promote healing in many clinical situations. However, the initial reference to its use has been attributed to Nygren (1838) for the treatment of the 'fistula dentalis', whilst Codman (1851) was the first to attempt to preserve the involved dental pulp.

According to Cvek (1989) calcium hydroxide became more widely known in the 1930s through the pioneering work of Hermann (1936) and the introduction of this material in the United States (Teuscher & Zander 1938, Zander 1939). The first reports dealing with successful pulpal healing using calcium hydroxide appeared in the literature between 1934 and 1941. Since then, and mainly after the Second World War, the clinical indications for its use were expanded and now this chemical is considered the best medicament

to induce hard tissue deposition and promote healing of vital pulpal and periapical tissues (Garcia 1983).

Although the overall mechanisms of action of calcium hydroxide are not fully understood, many articles have been published describing its biological properties which are achieved by the dissociation in Ca^{2+} and OH^- ions. The role of the high pH and the ionic activity in the healing process, diffusion through dentinal tubules, influence on apical microleakage and some clinical topics, such as the placement of the paste within the root canal, how to deal with interim flare-ups, the importance of periodic follow-up and redressings and the importance of the interappointment restoration, are examples of how this material has been evaluated since its introduction.

Along with the expanded clinical use of calcium hydroxide, the literature also discusses the use of various formulations and provides suggestions for mixing calcium hydroxide powder with other substances. As will be seen, many substances have been added to the powder to improve properties such as the antibacterial action, radiopacity, flow and consistency. Furthermore, pastes may be prepared at

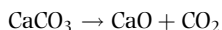
Correspondence: Professor W. P. Saunders, Adult Dental Care Education Group, University of Glasgow Dental School, 378 Sauchiehall Street, Glasgow G2 3JZ, UK.

the chairside before use but there are also many proprietary brands which have been tested in both animals and humans. However, it seems that no one paste has been proved to be superior than the others, either biologically or clinically.

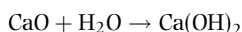
In spite of the variations, the literature lacks a classification of these different paste formulations; Holland (1994) has been the only author to suggest a classification according to the vehicle of the paste. The purpose of the present paper is to classify and describe the different formulations of calcium hydroxide, relating these to *in vitro* investigations, evaluation in laboratory animals and clinical studies where different pastes have been employed. This may help the clinician to choose the correct paste and to understand why a paste containing a specific vehicle should be employed clinically.

Chemical characteristics of calcium hydroxide

Limestone is a natural rock mainly composed of calcium carbonate (CaCO_3) which forms when the calcium carbonate solution existing in mountain and sea water becomes crystallized (Alliet & Vande Voorde 1988). The combustion of limestone between 900 and 1200°C causes the following chemical reaction:

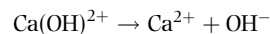


The calcium oxide (CaO) formed is called 'quicklime' and has a strong corrosive ability. When calcium oxide contacts water, the following reaction occurs:



Calcium hydroxide is a white odourless powder with the formula Ca(OH)_2 , and a molecular weight of 74.08. It has low solubility in water (about 1.2 g L^{-1} at 25°C), which decreases as the temperature rises; it has a high pH (about 12.5–12.8) and is insoluble in alcohol. This low solubility is, in turn, a good clinical characteristic because a long period is necessary before it becomes soluble in tissue fluids when in direct contact with vital tissues. The material is chemically classified as a strong base (Maisto & Capurro 1964, Maisto 1975, Torneck *et al.* 1983, Badillo *et al.* 1985, Lopes *et al.* 1986, 1996, Malo *et al.* 1987, Ricci & Travert 1987, Cvek 1989, Estrela 1994).

A chemical analysis of OH^- ionic liberation from calcium hydroxide allows the percentages of Ca^{2+} and OH^- ions that are released to be determined (Estrela 1994):



$$1 \text{ "Ca}^{2+} = 40.08$$

$$1 \text{ "OH}^- = 17.0 \Rightarrow 2 \text{ "OH}^- = 34$$

$$1 \text{ "Ca(OH)}_2 = 40.08 + 34 = 74.08$$

(molecular weight)

By way of a simple mathematical calculation, it is easy to obtain the percentage of OH^- and Ca^{2+} ions in the substance:

$$\left. \begin{array}{l} 74.08 \rightarrow 100\% \\ 34 \rightarrow X\% \end{array} \right\} X = 45.89\% \rightarrow 2\text{OH}^- = 45.89\%$$

$$\text{Ca}^{2+} = 100\% - 2\text{OH}^- \% \rightarrow 100\% - 45.89\%$$

$$\text{Ca}^{2+} = 54.11\%$$

The main actions of calcium hydroxide come from the ionic dissociation of Ca^{2+} and OH^- ions, and the action of these ions on vital tissue and bacteria generates the induction of hard tissue deposition and the antibacterial effect (Estrela 1994). However, when Ca^{2+} ions come into contact with carbon dioxide (CO_2) or carbonate ions (CO_3^{2-}) in tissue, calcium carbonate is formed which alters the mineralization process by the overall consumption of the Ca^{2+} ions (Maisto & Capurro 1964, Berbert 1978, Holland *et al.* 1979b). Furthermore, calcium carbonate has neither biological nor antibacterial properties (Estrela 1994).

When calcium hydroxide powder is mixed with a suitable vehicle, a paste is formed and, because the main component is calcium hydroxide, Maisto (1975) classified these formulations as alkaline pastes because of their high pH. According to some authors (Maisto 1975, Goldberg 1982, Leonardo *et al.* 1982), these pastes should have the following characteristics:

- 1 composed mainly of calcium hydroxide which may be used in association with other substances to improve some of the physicochemical properties such as radiopacity, flow and consistency;
- 2 non-setting;
- 3 can be rendered soluble or resorbed within vital tissues either slowly or rapidly depending on the vehicle and other components;
- 4 may be prepared for use at the chairside or available as a proprietary paste;
- 5 within the root canal system they are used only as a temporary dressing and not as a definitive filling material.

The easiest method to prepare a calcium hydroxide paste is to mix calcium hydroxide powder with water until the desired consistency is achieved. However, Leonardo *et al.* (1982) stated that a paste prepared with water or other hydrosoluble non-viscous vehicle does not have good physicochemical properties, because it is not radio-opaque, is permeable to tissue fluids and is rendered soluble and resorbed from the periapical area and from within the root canal. For these and the following reasons, Leonardo *et al.* (1982) recommended the addition of other substances to the paste:

- 1 to maintain the paste consistency of the material which does not harden or set;
- 2 to improve flow;
- 3 to maintain the high pH of calcium hydroxide;
- 4 to improve radiopacity;
- 5 to make clinical use easier;
- 6 not to alter the excellent biological properties of calcium hydroxide itself.

In essence, a calcium hydroxide paste for use in endodontics is composed of the powder, a vehicle and a radiopacifier. Other substances may be added to improve physicochemical properties or the antibacterial action.

Types of vehicles and their importance

It has been asserted that all biological actions of calcium hydroxide will be progressed by the ionic dissociation in Ca^{2+} and OH^- ions (Leonardo *et al.* 1982, Estrela 1994). The vehicle plays a most important role in the overall process because it determines the velocity of ionic dissociation causing the paste to be solubilized and resorbed at various rates by the periapical tissues and from within the root canal (Fava 1991). According to Fava (1991), the ideal vehicle should:

- 1 allow a gradual and slow Ca^{2+} and OH^- ionic release;
- 2 allow slow diffusion in the tissues with low solubility in tissue fluids;
- 3 have no adverse effect on the induction of hard tissue deposition.

Some *in vitro* studies have shown that the type of vehicle has a direct relationship with the concentration and the velocity of ionic liberation as well as with the antibacterial action when the paste is carried into a contaminated area (Marques *et al.* 1994, Estrela & Pesce 1996).

The differences in the velocity of ionic dissociation are related directly to the vehicle employed to obtain the paste. Furthermore, it is important to consider that viscosity is a measurement of the inner friction of a fluid. Thus, if a solution flows easily it has a low viscosity and the interactions between the particles are very small. As the paste is considered chemically to be a colloid (a solid dispersed into a liquid), this liquid (vehicle) may facilitate or inhibit the ionic dispersion from the paste; the lower the viscosity, the higher will be the ionic dissociation (Estrela 1994).

In general, three types of vehicles are used: aqueous, viscous or oily (Fava 1991, Holland 1994, Lopes *et al.* 1996). The first group is represented by water-soluble substances, including water, saline, dental anaesthetics with or without a vasoconstrictor, Ringer's solution, aqueous suspension of methylcellulose or carboxymethylcellulose and anionic detergent solution.

When calcium hydroxide is mixed with one of these substances, Ca^{2+} and OH^- are rapidly released. This type of vehicle promotes a high degree of solubility when the paste remains in direct contact with the tissue and tissue fluids, causing it to be rapidly solubilized and resorbed by macrophages. The root canal may become empty in a short period, delaying the healing process (Esberard 1992). From a clinical standpoint, this means that the root canal must be re-dressed several times until the desired effect is achieved, thereby increasing the number of appointments (Fava 1991).

Some viscous vehicles are also water-soluble substances that release Ca^{2+} and OH^- ions more slowly for extended periods. They promote a lower solubility of the paste when compared with aqueous vehicles, probably because of their high molecular weights (Lopes *et al.* 1998).

According to Silva (1988) the high molecular weight of these vehicles minimizes the dispersion of calcium hydroxide into the tissue and maintains the paste in the desired area for longer intervals; this factor prolongs the action of the paste, and Ca^{2+} and OH^- ions will be given off at lower velocity. It is through this mechanism that these pastes remain in direct contact with vital tissues for extended time intervals. As a viscous vehicle-containing paste may remain within the root canal for a 2–4 month interval, the number of appointments and re-dressings of the root canal is drastically reduced (Fava 1991). Some examples of viscous vehicles are glycerine, polyethyleneglycol and propylene glycol.

Oily vehicles are non-water-soluble substances that promote the lowest solubility and diffusion of the paste

within the tissues (Lopes 1987, Marques *et al.* 1994, Lopes *et al.* 1996). Pastes containing this kind of vehicle may remain within the root canal for longer than the pastes containing aqueous or viscous vehicles. Some examples of oily vehicles are olive oil, silicone oil, camphor (the essential oil of camphorated parachlorophenol), metacresylacetate and some fatty acids such as oleic, linoleic and isostearic acids (Holland *et al.* 1979a, 1983, Kawakami *et al.* 1987a, Lopes 1987, Matsumoto *et al.* 1989, Caputo 1997, Lopes *et al.* 1998).

The description of the following clinical example may clarify why the type of vehicle is so important. In cases of dental replantation, as soon as treatment is performed, a paste with an aqueous vehicle should be employed because of the need for rapid ionic release and pH turnover to avoid replacement resorption. Subsequently, a calcium hydroxide paste with a viscous vehicle should be used in the following periodical redressings, because the paste may remain in the root canal for a longer period. During this time the pH will be maintained in the area and a slow ionic release will occur. The alkaline properties of the calcium hydroxide in such a paste will only be exhausted after a long period (Leonardo *et al.* 1993a).

Summarizing, clinical situations that require a rapid ionic liberation at the beginning of treatment require an aqueous vehicle-containing calcium hydroxide paste, whilst in clinical situations that require a gradual and uniform ionic liberation, a viscous vehicle-containing paste should be used. Pastes containing oily vehicles have restricted use and are only employed in those clinical situations that require a very slow ionic dissociation.

Thus, the vehicle used with calcium hydroxide represents a very important component of these pastes, and for this reason classification of these pastes has been made according to the type of the vehicle.

Aqueous vehicles

Pastes prepared at the chairside

Water. The easiest method to prepare a calcium hydroxide paste is to mix the powder with water. However, the literature describes different 'types' of water with which to prepare the paste, including sterile water, distilled water, sterile distilled water, bidistilled water and sterile bidistilled water. Usually this paste is prepared on a sterile glass slab with a sterile spatula. The powder is mixed with the liquid

until the desired consistency is achieved. The paste is carried into the root canal by any available method.

Some chemical characteristics of such a paste were evaluated by different authors, including its pH (Conrado *et al.* 1965, Leonardo *et al.* 1992), ionic dissociation (Leonardo *et al.* 1992) and its diffusion through dentine (Leonardo *et al.* 1993a, Esberard *et al.* 1996). The antibacterial effect was studied by Martins *et al.* (1979), Bremer (1980) and Di Fiore *et al.* (1983), whilst the solvent action was evaluated by Hasselgren *et al.* (1988).

This paste has been evaluated for the tissue reactions when implanted in rat subcutaneous connective tissue (Mitchell & Shankwalker 1958), for its ability to induce hard tissue deposition in apexification procedures in non-vital dog teeth (Silva *et al.* 1991) and in replacement resorption in replanted rat teeth (Okamoto *et al.* 1996).

In human clinical studies this paste has been indicated for capping of vital pulp tissue after pulpotomy (Russo *et al.* 1974b), as a long-term dressing in cases of non-vital teeth with associated large periapical lesions (Sahli 1988, Souza *et al.* 1989) and in apexification procedures (Taintor 1977, Winter 1977, Harrison & Rakusin 1985, Yates 1988).

To improve the radiopacity of the paste, some authors (Webber *et al.* 1981, Kleier *et al.* 1985, Moraes *et al.* 1992) suggest adding barium sulphate (one part) to the calcium hydroxide powder (eight parts) before the preparation of the paste.

Sterile water. In animals, a paste containing such a vehicle was evaluated in apexification procedures in dog teeth (Vojinovic & Srnie 1975) and as a dressing in infected root canals (Matsumiya & Kitamura 1960). An interesting *in vitro* study was performed by Kehoe (1987) to evaluate the pH reversal after bleaching of pulpless teeth.

In humans this paste has been indicated for direct pulp capping (Sommer *et al.* 1975, Horsted *et al.* 1985), pulpotomy and apexogenesis (Corpron & Dowson 1970, Goldman 1974, Sommer *et al.* 1975, Naulin-Ifi 1986, Sheehy & Roberts 1997), apexification procedures (Erdogan 1997), as an apical plug before gutta-percha filling in non-vital teeth with an open apex (Michanowicz & Michanowicz 1967) and in cases of internal resorption with perforation of the dentinal wall (Barclay 1993).

Distilled water. Pastes containing this vehicle were chemically evaluated for its pH (Conrado *et al.* 1965,

Leonardo *et al.* 1992, Fuss *et al.* 1996), ionic dissociation (Leonardo *et al.* 1992, Marques *et al.* 1994, Simon *et al.* 1995, Felipe 1998), tissue solvent action (Morgan *et al.* 1991, Yang *et al.* 1995) and antibacterial effect (Siqueira & Uzeda 1997), and compared with other substances for apical closure induction (Smith *et al.* 1984).

It is important to highlight that Crabb (1965) was the first to use this paste in the treatment of large periapical lesions. He said: '...perhaps the locally destructive action of calcium hydroxide with its high pH, acting as a chemical cautery, might effect breakdown of the epithelium'.

This paste was evaluated for tissue reaction when implanted in the subcutaneous connective tissue (Souza *et al.* 1977) and pulpotomy of rats (Silva *et al.* 1996). It was evaluated for its effect on dentine (Holland *et al.* 1978a), as a direct pulp capping material (Ogawa *et al.* 1974, Holland *et al.* 1980a, 1982), as a temporary dressing material after vital pulp extirpation (Sekine *et al.* 1963a, Holland *et al.* 1978b, 1981), in apexification procedures (Binnie & Rowe 1973) and for the treatment of chronic periapical lesions in dogs (Holland *et al.* 1979b).

Clinically, it has been employed for the induction of hard tissue deposition in apexification procedures (Saad 1988, Yang *et al.* 1990), in pulpotomy of deciduous (Androni & Russo 1974) or permanent teeth (Acosta & Heredia 1986), as a temporary dressing after vital pulp extirpation (Leonardo 1973) and in non-vital teeth with associated chronic periapical disease (Crabb 1965, Sardi *et al.* 1995), in internal resorption (Souza Neto *et al.* 1991), in perforations (Bogaerts 1997) and to arrest external cervical resorption after bleaching of pulpless teeth (Santos 1996).

It has been suggested that iodoform or bismuth carbonate should be added to improve the radiopacity of the paste (Holland *et al.* 1981, Rezende 1982).

An old suggestion proposed by Yacometti (1952) was to add penicillin to a calcium hydroxide-distilled water paste to be used as a pulp capping material.

Sterile distilled water. This paste was evaluated for human direct pulp capping (Patterson & Van Huysen 1954), in apexification procedures (Wechsler *et al.* 1978) and, in animal studies, for its intradentinal calcium diffusion (Guigand *et al.* 1997).

Bidistilled water. According to Laurichesse (1980) it was Albu who first used bidistilled water as the vehicle of the paste in normal clinical cases. However, in cases of

infected non-vital teeth, some drops of camphorated parachlorophenol were added to the paste.

Sterile bidistilled water. This vehicle was recommended by Breillat *et al.* (1983a,b) for human apexogenesis and apexification procedures.

Saline or sterile saline. According to the United States Pharmacopeia (1989) saline is prepared by dissolving 9 g of sodium chloride in water to make 1000 mL.

The following characteristics were evaluated when saline or sterile saline were the vehicles of a calcium hydroxide paste: pH (Anthony *et al.* 1982, Estrela *et al.* 1995b, Peniche *et al.* 1996), ionic dissociation (Foster *et al.* 1993, Marques *et al.* 1994, Estrela *et al.* 1995b, Simon *et al.* 1995, Gomes *et al.* 1996), tissue solvent action (Wakabayashi *et al.* 1995), antibacterial effect (Safavi *et al.* 1985, Stuart *et al.* 1991, Barbosa *et al.* 1995, Estrela *et al.* 1995a, Siqueira & Uzeda 1996, Sydney 1996), apical microleakage (Porkaew *et al.* 1990, Siqueira & Fraga 1995) and some methods to remove the paste from within the root canal (Guignes *et al.* 1991).

When this paste was implanted in vital tissues, the reactions were evaluated by Pissiotis & Spangberg (1990) and Wakabayashi *et al.* (1993). In animal studies, the paste was evaluated in direct pulp capping (Tziafas & Molyvdas 1988) and in the apexification of immature non-vital dog (Citrome *et al.* 1979) and monkey teeth (Nevins *et al.* 1978) and to arrest inflammatory resorption in replanted dog teeth (Trope *et al.* 1992, 1995).

Clinically, it was evaluated in human non-vital immature teeth (Cvek 1972, Cvek & Sundstrom 1974, Gallagher & Mourino 1979, Biesterfeld & Taintor 1980, Yates 1988), in perforations (Bogaerts 1997), in internal resorption at the site of an intra-alveolar root fracture (Cvek 1974), in external inflammatory root resorption (Rabie *et al.* 1988), in luxated non-vital teeth (Cvek 1992), as an antibacterial dressing in infected teeth (Barbosa *et al.* 1995), in infected teeth with associated acute or chronic periodontitis (Orstavik *et al.* 1991), in non-vital infected teeth with associated cutaneous sinus tract (Foster *et al.* 1992), in endodontic retreatment after endodontic and surgical failures (West & Lieb 1985) and as a dressing after partial pulpectomy (Engstrom & Spangberg 1967).

Recently, Yoshida *et al.* (1994) proposed a new formulation, adding α -tricalciumphosphate to the calcium hydroxide powder and saline for capping amputated pulps. Sazak *et al.* (1996) have suggested

adding Ledermix (Lederle Lab., München, Germany) to a calcium hydroxide-saline paste to be used after pulpotomy with the purpose of reducing postoperative pain and inflammation.

Anaesthetic solutions. Anaesthetic solutions, with or without a vasoconstrictor, have been used as the vehicle of the paste because these solutions are readily available, sterile and easy to handle.

It is interesting to note that most of these solutions have an acid pH, but when mixed with the calcium hydroxide powder, the final paste has a high pH which is maintained over time. Furthermore, they promote a rapid ionic release (Stamos *et al.* 1988, Marques *et al.* 1994, Prokopowitsch 1994, Estrela *et al.* 1995b, Fuss *et al.* 1996, Peniche *et al.* 1996).

As the final paste lacks radiopacity, some authors add barium sulphate (one part) to calcium hydroxide powder (four parts) (Dumsha & Gutmann 1985). Marais (1996) believes this proportion is not necessary for a high radiopacity and uses a 1:8 ratio. To increase the antibacterial property of the paste, Teplitsky (1986) suggested adding one drop of camphorated *p*-chlorophenol when used as a dressing in infected non-vital cases.

This paste has been indicated for human apexification procedures by Goldman (1974), Taintor (1977), Webber *et al.* (1981) and Webber (1984) and as a pulp capping material by Armstrong & Hoffman (1962).

Ringer's solution. According to the United States Pharmacopeia (1989), this solution has sodium chloride (8.6 g), potassium chloride (0.3 g), calcium chloride (0.33 g) and water to 1000 mL.

Historically, it was Granath (1959) who was the first to describe the use of such a paste in cases of traumatic injuries, although some authors (Martin & Crabb 1977, Ricci & Travert 1987, Foreman & Barnes 1990, Fava 1991) believe he was also the first to employ a calcium hydroxide paste in root-end induction procedures. This is not correct because the oldest reference in which a calcium hydroxide paste was used for root-end hard tissue deposition is Marmasse (1953); this author was the first to recommend a resorbable paste for this purpose using a proprietary brand called Calxyl, which will be discussed later.

Chemically, this paste was evaluated for alterations in the pH of dental structures when used as a temporary dressing (Tronstad *et al.* 1981).

Clinically, it has been evaluated in indirect pulp capping (Nyborg 1955), in apexification procedures (Cvek 1972) and as a temporary dressing both after vital pulpectomy (Nyborg & Tullin 1965, Stromberg 1969) and in non-vital teeth (Cvek 1976), and it has been widely used in the treatment of post-traumatic sequelae such as luxation and replantation (Cvek 1973, 1989).

Methylcellulose and carboxymethylcellulose. Historically, methylcellulose was the vehicle of a paste widely used in South America, mainly in Argentina. Maisto & Capurro (1964) introduced a paste composed of equal volumes of calcium hydroxide powder and iodoform mixed with a 5% aqueous solution of methylcellulose.

Biological responses were evaluated after the implantation of this paste in subcutaneous connective tissue of the rat (Souza *et al.* 1977). In animal studies, the induction of a hard tissue barrier after apexification procedures was evaluated in dogs (Holland *et al.* 1971) and monkeys (Manfredi 1971). Its antibacterial effect was evaluated by Di Fiore *et al.* (1983). In human apexification procedures it was recommended by Maisto & Capurro (1964), Heithersay (1970a, b) and Holland *et al.* (1973), whilst in indirect pulp capping it was recommended by Massler *et al.* (1957) and Krakow *et al.* (1974).

Laurichesse (1980) proposed the following modification of the original formula: calcium hydroxide and iodoform in a ratio 2/3:1/3, two drops of camphorated parachlorophenol and a 3% aqueous solution of methylcellulose as the vehicle.

More recently, Giro *et al.* (1993) proposed the use of carboxymethylcellulose or, according to the United States Pharmacopeia (1989), polycarboxymethylether of cellulose, as the vehicle in the following formula: 0.5 g of calcium hydroxide to 0.5 mL of a 1.66% solution of carboxymethylcellulose; in another suggested formulation, 0.25 g of zinc oxide was added for radiopacity. Both formulations were evaluated after pulpotomy in dog teeth.

Anionic detergent solution. It is well known that detergents decrease the surface tension between two surfaces and facilitate substance penetration. This is perhaps the reason why calcium hydroxide powder has been mixed with an aqueous detergent solution to increase the action of the calcium hydroxide deeper into the tissues.

Unfortunately, only two studies have appeared in the literature dealing with these substances. Barbosa

et al. (1994) tested the antibacterial effect of a paste composed of calcium hydroxide and sodium lauryl diethyleneglycol ether sulphate, and Peniche *et al.* (1996) evaluated the pH of a paste containing calcium hydroxide and sodium lauryl sulphate.

Proprietary brands

Calxyl (Otto & Co., Frankfurt, Germany). This paste represents the oldest manufactured calcium hydroxide paste and was introduced by Hermann (1920). He was the first to suggest this material be employed as a dressing with the purpose of maintaining vital pulp tissue and inducing healing by the formation of a calcified barrier at the site of amputation (Masterton 1964). According to Webber (1984), Hermann was looking for a biological and compatible substance when in direct contact with pulpal and periapical tissues because he was dissatisfied with the cytotoxic medicaments used at that time.

This paste is a solution of calcium hydroxide in water with the addition of the following blood salts: sodium carbonate, sodium chloride, calcium chloride, potassium chloride and traces of magnesium. It is manufactured both without (red label) and with a radiopacifier (blue label) (Castagnola 1956).

Calxyl became very popular and was extensively studied for use in the maintenance of pulp vitality. A large number of studies appeared in the literature between 1930 and 1950. The interested reader should consult the review by Masterton (1964).

It is important to note that Rohner (1940) used this paste to demonstrate the deposition of an apical barrier over the pulp remnant after vital pulpectomy. This study was the first to show that deposition microscopically.

Marmasse (1953) was the first to indicate Calxyl and other resorbable pastes such as Walkhoff's paste and Dentinogene (Lab. Pierre Roland, Paris, France) in cases requiring apexification:

... the use of a resorbable paste (Calxyl, Walkhoff, Dentinogene) will allow invagination of the periodontal tissue inside the root canal sealing off the apical foramen by deposition of cementum, allowing root ingrowing and apical shape although the absence of a vital pulp.

Calxyl has been evaluated chemically for its pH (Fuss *et al.* 1996), ionic dissociation (Tamburic *et al.* 1993, Beltes *et al.* 1997) and its effect upon human serum proteins (Rantanen & Louhivuori 1959). Histologically, the response of implants in rat subcutaneous tissue

was evaluated by Souza *et al.* (1977), after pulpotomy of monkey teeth (Masterton 1966) and during apexification in dogs (Binnie & Rowe 1973) and monkeys (Chosak *et al.* 1997).

In humans this paste has been employed for direct pulp capping and pulpotomy (Hess 1950, Masterton 1966), apexification (Ehrmann & Geurtsen 1985, Rotstein *et al.* 1990) and in orthograde root canal treatment (Hermann 1935a,b,c, Juge 1959). Varella *et al.* (1966) suggested adding a corticosteroid substance (2% methylprednisolone stearate) to Calxyl for direct pulp capping in human teeth to reduce post-operative pain and inflammation.

Pulpdent and Tempcanal (Pulpdent Corp., Brookline, MA, USA). Pulpdent is a commercial paste consisting of calcium hydroxide (52.5%) in an aqueous suspension of methylcellulose (Goldberg 1982). It was employed initially in direct pulp capping and pulpotomy (Berck 1950) and became more popular when Heithersay (1975) used it for apexification and other clinical situations such as perforations, large periapical lesions and external resorption.

Its chemical properties were evaluated for its antibacterial effect (Stevens & Grossman 1983, Stuart *et al.* 1991), solvent effect (Metzler & Montgomery 1989), pH (Conrado *et al.* 1965) and composition (Freitas 1982). Biologically it was studied after implantation in rat subcutaneous connective tissue (Souza *et al.* 1977), after pulpotomy in dog teeth (Berck 1950) and in the indirect pulp capping (Tronstad & Mjor 1972) and apexification of pulpless monkey teeth (Weinstein & Goldman 1977).

In humans it has been used successfully in indirect pulp capping (Horsted *et al.* 1985), direct pulp capping (Berck 1957, Shankle & Brauer 1962), pulpotomy (Berck 1957, Krakow *et al.* 1977), apexification procedures (Heithersay 1970b, Simpson 1970, Anthony & Senia 1981, Feiglin 1985, Thater & Marechaux 1988), post-traumatic apexification (Fortier *et al.* 1991, Kleier & Barr 1991), apexification during active orthodontic movement (Anthony 1986), apexification in adults (Parashos 1997), apexification subsequent to apical curettage (Ohara & Torabinejad 1992), as an apical plug prior the obturation of the root canal (Senzamici & Tesini 1977), in the treatment of chronic periapical lesions (Vernieks 1978, Girard & Holz 1985), in the management of post-bleaching cervical resorption (Gimlin & Schindler 1990) and many other clinical indications described by Heithersay (1975, 1985). When the paste is to be condensed

vertically, a thicker mix is obtained by adding more calcium hydroxide powder to the paste (Burke 1976, Stock 1985).

Shay *et al.* (1960) introduced a paste composed of Pulpdent, 50 mg of Achromycin (Pfizer), a broad-spectrum antibiotic and three drops of camphorated parachlorophenol, and evaluated it both clinically as a direct pulp capping agent and experimentally for its antibacterial activity.

Tempcanal is a similar calcium hydroxide in aqueous methylcellulose but modified to allow flow through 22, 25 and 27 gauge needles (Milosevic 1991) and has barium sulphate to improve radiopacity (Luvizotto *et al.* 1996). The properties were evaluated for ionic dissociation both *in vitro* (Beltes *et al.* 1997) and within the root canal (Deardorf *et al.* 1994) and for paste residue after irrigation (Guignes *et al.* 1991).

Calvital (Neo Dental Chemical Products Co., Tokyo, Japan). This paste was originally proposed by Sekine *et al.* (1963b) and is composed of a powder and a liquid. The powder has the following composition: calcium hydroxide (78.5%), iodoform (20%), guanoflacin (0.1%) and sulphathiazol (1.4%), whilst the liquid is composed of T-cain (0.5%), propyleneglycol (50%) and distilled water (49.5%). This paste was evaluated for direct pulp capping (Nagakubo 1969, Sekine *et al.* 1971, Asano *et al.* 1974), pulpotomy in deciduous teeth (Taguchi 1972, Imanishi 1980, Kokubo 1981), pulpotomy in permanent teeth (Sekine *et al.* 1963a), intracanal dressing after vital pulpectomy (Asano *et al.* 1974) and as a final filling coupled with gutta-percha points (Tsuchima 1970). Moreover, tissue reactions were evaluated when this paste was implanted in rat subcutaneous connective tissue (Souza *et al.* 1977) and as a dressing in the treatment of pulpless dog teeth (Holland *et al.* 1978a, 1979c, Shibuya 1980).

However, as time went by, some suggestions were made to modify the original composition to improve its properties. The first of these was proposed by Kitagawa (1969) using the same powder composition but a liquid composed of T-cain (0.5%), polysorbate 20 (30%) and distilled water (69.5%). This formulation was evaluated as a dressing after vital pulp extirpation (Kitagawa 1969) and in non-vital teeth of older patients (Eda *et al.* 1985).

The second modification was proposed by Asai *et al.* (1981). The powder was composed of calcium hydroxide (67%), iodoform (29%), CMC (1%), and others (3%), whilst the liquid was composed of Tween

20 (30%), propyleneglycol (10%) and sterile water (60%). This paste was evaluated in human direct pulp capping (Asai *et al.* 1981) and in immature dog teeth (Matsuzaki *et al.* 1990).

The third modification was proposed by Ida *et al.* (1989) using the original powder and a liquid composed of diethylaminoethylhydrochloride (0.5%), guanofuracin (0.02%) and distilled water (99.48%). This paste was only tested for its pH (Ida *et al.* 1989).

Reogan (Vivadent, Schaan, Liechtenstein). This paste is composed of calcium hydroxide, barium sulphate, casein and magnesium hydroxide (Mackie *et al.* 1988). The ionic release was evaluated by Beltes *et al.* (1997). This paste was described by Nyborg (1955) and has been indicated mainly for human apexification procedures (Mackie *et al.* 1988, 1994) and as a routine dressing in vital or non-vital teeth with or without periapical lesions radiographically (Kennedy *et al.* 1967).

Calasept (Scania Dental AB, Knvista, Sweden). This paste was introduced in the 1980s and, according to Ghose *et al.* (1987), is composed of calcium hydroxide (56%), calcium chloride (8 mg), sodium chloride (0.35 mg), sodium bicarbonate (4 mg), potassium chloride (8 mg) and water sufficient for 100 g of the paste.

Some evaluation studies were performed regarding its pH and ionic dissociation (Leonardo *et al.* 1992, Nerwich *et al.* 1993, Beltes *et al.* 1997), antibacterial effect (Bystrom *et al.* 1985, Reit & Dahlen 1988, Sjogren *et al.* 1991), tissue solvent effect (Andersen *et al.* 1992) and effect on apical microleakage (Porkaew *et al.* 1990), and in animal studies, it was evaluated in replanted dog teeth (Lengheden *et al.* 1991).

In human apexification procedures, it was employed by Ghose *et al.* (1987) in indirect pulp capping (Leksell *et al.* 1996), in direct pulp capping (Nosrat & Nosrat 1998), in retreatment cases (Danin *et al.* 1996, Sundqvist *et al.* 1998) and in luxated non-vital teeth (Cvek 1992). A soluble iodide organic substance (Dionosil; Glaxo, Greenford, UK) may be added for a better radiographic intracanal visualization of the paste (Tavano *et al.* 1978, Allard *et al.* 1987).

Hypocal (Ellinan Co., Hewlitt, NY, USA). According to Goldberg (1982) this paste is composed of calcium hydroxide (45%), barium sulphate (5%), hydroxymethylcellulose (2%) and water (48%). However, Ida *et al.* (1989) presented the following formula: calcium hydroxide (45%), barium sulphate

(5%), glycolcellulose (2%) and distilled water (48%). Its pH was evaluated by Conrado *et al.* (1965) and Ida *et al.* (1989). In animal studies this paste was evaluated in the treatment of root resorption in replanted dog teeth (Gregoriou *et al.* 1994).

Clinically, it has been evaluated in the apexification of human deciduous teeth (O'Riordan 1980) and human permanent teeth (Breillat *et al.* 1983b, Yates 1988, Kleier & Barr 1991, Mackie *et al.* 1994).

Calcicur (VOCO, Auxhaven, Germany). According to the manufacturer, this paste is composed of radiopaque calcium hydroxide in an aqueous vehicle. Its ionic release was evaluated by Beltes *et al.* (1997).

DT Temporary dressing (Dental Therapeutics AB, Nacka, Sweden). According to the manufacturer, this paste is composed of unoxxygenated calcium hydroxide and sterilized distilled water.

Calcipulpe (Specialités Septodont, Saint-Maur, France). This paste is composed of calcium hydroxide and carboxymethylcellulose and was evaluated for its ionic liberation (Tamburic *et al.* 1993) and pulp reactions after direct human pulp capping (Nagakubo 1969, Sekine *et al.* 1971).

Hidropulpe (Lab. Zizine, France). This paste is composed of calcium hydroxide and barium sulphate in a solution of methyl benzoate. This paste was cited by Breillat & Laurichesse (1986) and Deveaux *et al.* (1986) but no studies have appeared in the literature evaluating its chemical or biological properties.

Serocalcium (Casa Wild, Basel, Switzerland). According to Castagnola (1956) and Masterton (1964), this paste has a similar composition to Calxyl and has been employed for direct pulp capping and pulpotomy of human teeth (Hess 1950, Patterson & Van Huysen 1954, Rantanen & Louhivuori 1959, Tuero 1974).

Calcigel (Lab. Septodont, France), *Endocal (Lab. Biodica, France)*, *Hydroxine (Lab. Ato Zizine, France)*. These three proprietary brands are basically composed of calcium hydroxide, methylcellulose and water (Rocca 1993).

Acricol (Bames-Hind Laboratories, USA). This paste is composed of 9-aminoacridine hydrochloride (0.2%), benzalkonium chloride (0.1%), calcium hydroxide (28%) and barium sulphate (5%). Benzalkonium chloride is a cationic detergent and thus a water-

soluble vehicle. This paste was evaluated for pulp capping in human teeth (Nagakubo 1969, Sekine *et al.* 1971)

Calnex (Associated Dental Products Ltd, London, UK). This paste contains sterilized calcium hydroxide plus blood serum salts and methylcellulose and was evaluated in human pulpotomies by Santini (1985).

Viscous vehicles

Pastes prepared at the time of use

Glycerine. Glycerine is a viscous, colourless transparent liquid with a characteristic odour, sweetish in taste and hygroscopic. It can be mixed with water, acetone, alcohol and other glycols in any proportion but is insoluble in chloroform, ether, benzene and volatile oils. Its molecular weight is 92.02 (Lopes *et al.* 1996, 1998).

Because of its hygroscopic properties, glycerine is very useful as a moistening substance and, as it is soluble in water, it is easily removed. Furthermore, it is non-toxic (Olson & Hoover 1975) and is used as an intracanal lubricant (Walton & Torabinejad 1989).

The first use of a calcium hydroxide paste with glycerine in its formula was reported by Steiner *et al.* (1968) in a paste composed of calcium hydroxide, camphorated parachlorophenol, barium sulphate and glycerine. This paste was employed for root-end closure of immature non-vital teeth.

The paste is obtained by mixing calcium hydroxide with synthetic glycerine as proposed by Çaliskan *et al.* (1994) and Rivera & Williams (1994) and has been evaluated for its antibacterial effect by Siqueira & Uzeda (1997). A radiopacifier may be added to improve radiopacity, such as iodoform (Salamat & Rezai 1986) or barium sulphate in a 1:8 ratio with the calcium hydroxide powder (Çaliskan & Sen 1996, Çaliskan & Turkun 1997).

Siqueira & Uzeda (1996) added camphorated parachlorophenol to a calcium hydroxide-glycerine paste in order to extend its antibacterial spectrum against some species of obligate and facultative anaerobic bacteria. The addition of zinc oxide or iodoform to improve radiopacity of the paste did not interfere with antibacterial action (Siqueira *et al.* 1996, 1997). Such radiopacifiers may be added to the paste in a 1:3 or 1:6 ratio with calcium hydroxide powder (Siqueira 1997).

This paste has been used in cases of chronic abscesses with extraoral fistulae (Salamat & Rezai 1986,

Çaliskan *et al.* 1994), acute abscesses or chronic periapical lesions (Çaliskan & Sen 1996), internal resorption with or without root perforation (Çaliskan & Turkun 1997) and to repair a fractured root (Çaliskan & Pehlivan 1996) even with an associated site of internal resorption (Çaliskan & Turkun 1996).

Polyethyleneglycol. Polyethyleneglycol is a viscous, colourless liquid with a characteristic odour and it is slightly hygroscopic. It is miscible in any proportion with water, acetone, alcohol and other glycols but is insoluble in ether and benzene (Lopes *et al.* 1996, 1998).

According to the United States Pharmacopeia (1989) it is a polymer of ethyleneglycol and water, represented by the formula $H(OCH_2CH_2)_nOH$ in which n represents the average number of oxyethylene groups. Its pH ranges between 4.5 and 7.5.

These pastes were evaluated for their pH (Estrela *et al.* 1995b) and ionic release (Marques *et al.* 1994, Estrela *et al.* 1995a). Tissue reactions were evaluated after their implantation in rat subcutaneous connective tissue (Mauricio *et al.* 1987, Zelante *et al.* 1992) and after pulpotomy in dog teeth (Giro *et al.* 1993).

A paste composed of calcium hydroxide (70%), iodoform (30%) and polyethyleneglycol 1500 as the vehicle was employed by Bellacosa *et al.* (1993) in a clinical case of external/internal resorption, whilst a paste composed only of the powder and polyethyleneglycol 400 was suggested by Santos (1996) for use in the treatment of external cervical resorption after bleaching of pulpless teeth.

Maeda (1960) introduced a paste containing calcium hydroxide, polyethyleneglycol 1500 as a base and sulphisomidine and eugenol as antibacterial agents. In the following year, Kurimoto (1961) tested the same paste as an intracanal dressing, with and without the antibacterial agents, in human infected pulpless teeth with associated periapical lesions and found a high frequency of favourable cases.

Leonardo *et al.* (1976) introduced a paste containing calcium hydroxide (2 g), polyethyleneglycol 400 (1.75 mL), barium sulphate (1 g) for radiopacity and hydrogenized colophony (0.05 g) to improve physical properties. Later Leonardo & Leal (1991) replaced the barium sulphate by zinc oxide in the same proportion. Furthermore, 0.15 mL of camphorated parachlorophenol was added to the paste when used in cases of infected root canals; this paste is now a proprietary brand.

A simple paste may be obtained by mixing calcium hydroxide (3 g) with polyethyleneglycol 400

(1.75 mL) (Zelante *et al.* 1992). However, Pinto & Lessi (1984) and Lessi & Alvares (1988) suggested mixing the calcium hydroxide powder to a creamy consistency with iodoform (30%) and polyethyleneglycol 1500 (70%). Another formula has been suggested (Zelante *et al.* 1992): calcium hydroxide (3 g), zinc oxide (3 g) or iodoform (1.5 g) and polyethyleneglycol 400 (3.5 mL). Ulyssea *et al.* (1992) suggested using barium sulphate as the radiopacifier in a 1:4 ratio with the calcium hydroxide powder.

Propyleneglycol. Propyleneglycol is a clear, colourless, odourless liquid with a slightly characteristic taste resembling that of glycerine. Chemically, it is a dihydric alcohol with a syrupy consistency, hygroscopic in nature and non-toxic that can be mixed with water, acetone and alcohol in any proportion. According to the United States Pharmacopeia (1989), its formula is $CH_3CH(OH)CH_2OH$ and its molecular weight is 76.09. It is widely employed as a useful vehicle for pharmaceutical preparations such as antihistamines, barbiturates, paracetamol and those used for parenteral administration. Moreover, this substance is a suitable vehicle for members of the vitamin B group, pyrazolines, aspirin and chloral hydrate (Balcow & Martindale 1972, Bhat & Walkevar 1975, Bairy *et al.* 1993, Simon *et al.* 1995, Lopes *et al.* 1996).

Bhat & Walkevar (1975) demonstrated a strong antibacterial action of propyleneglycol against common microorganisms found in infected root canals and suggested its wider application in endodontics as a gentle vehicle for intracanal medicaments. Its hygroscopic nature permits the absorption of water, which ensures a good sustained release of calcium hydroxide for long periods. Another advantage of this substance is its consistency, which improves the handling qualities of the paste (Bairy *et al.* 1993, Simon *et al.* 1995). Simon *et al.* (1995) recommend propyleneglycol as the best vehicle in calcium hydroxide preparation.

The first report using a calcium hydroxide paste containing this vehicle was by Saijo (1957), who added antibacterial agents and asbestos powder. Laws (1962) suggested the use of 10 g of calcium hydroxide powder with 7.5 mL of propyleneglycol and later suggested the following formulation: calcium hydroxide (four parts), barium sulphate (one part) for radiopacity and propyleneglycol (Laws 1971). Holland (1994) suggested using a simplified formulation of calcium hydroxide, iodoform and propyleneglycol, as did Soares *et al.* (1996) but replacing the iodoform for zinc oxide to improve radiopacity.

These pastes have been evaluated for their pH (Peniche *et al.* 1996), ionic dissociation (Simon *et al.* 1995, Felipe 1998), effect on apical microleakage (Siqueira & Fraga 1995) and tissue reactions after implantation in the rat subcutaneous connective tissue (Souza *et al.* 1977) and after pulpotomy in dog teeth (Bittencourt *et al.* 1997). In humans it was evaluated as an intracanal dressing after vital pulpectomy (Saiji 1957, Machida 1960, Sekine *et al.* 1963a) and for the non-surgical treatment of large periapical lesions (Hussey & Kennedy 1990).

Proprietary brands

Calen (S.S. White – Artigos Dentários, Rio de Janeiro, RJ, Brazil). This paste is the proprietary brand of Leonardo & Leal's paste, the formulation of which is: calcium hydroxide (2.5 g), zinc oxide (0.5 g), hydrogenized colophony (0.05 g) and polyethyleneglycol 400 (1.75 mL). This is the unique proprietary brand of a calcium hydroxide paste containing this viscous vehicle.

Some chemical characteristics were evaluated regarding pH and ionic release (Leonardo *et al.* 1992) and its diffusion through dentine (Leonardo *et al.* 1993a). In animal studies, this paste was evaluated for pulpotomy (Bittencourt *et al.* 1997) and apexification of non-vital immature dog teeth (Silva *et al.* 1991) and for tissue reactions in rat subcutaneous connective tissue (Motta *et al.* 1997).

In humans it has been used in apexification procedures (Leonardo *et al.* 1978a,b, Sahli 1989), in the treatment of large periapical lesions originating from infected root canals (Sahli 1988, Gutmann & Fava 1992), as an interappointment dressing in cases of vital pulpectomy (Fava 1992, 1994), in acute apical periodontitis (Fava 1998) and in endodontic retreatment after endodontic and surgical failures (Fava 1996).

Calen + camphorated parachlorophenol (S.S. White – Artigos Dentários, Rio de Janeiro, RJ, Brasil). Leonardo *et al.* (1991) added camphorated parachlorophenol (CMCP, 0.15 mL) to the original Calen formulation to be used in cases of non-vital and infected teeth with associated periapical lesions. This paste was chemically evaluated for its pH and ionic release (Leonardo *et al.* 1992) and diffusion through dentine (Leonardo *et al.* 1993b).

It was also evaluated for its antibacterial action when used as a dressing after biomechanical

preparation on anaerobic bacteria of infected non-vital teeth (Assed *et al.* 1996). It was also employed in apexification procedures in dog teeth (Silva *et al.* 1991, Leonardo *et al.* 1993b), and the healing process of induced chronic periapical lesions in dog teeth has been studied (Leonardo *et al.* 1994, 1995).

The combination of calcium hydroxide and camphorated parachlorophenol was proposed in the 1960s by Kaiser (1964) and Frank (1964, 1966). In the following decades this was not favoured by some authors who believed there was no necessity to add a cytotoxic agent (CMCP) to calcium hydroxide (Spangberg 1994). However, in the 1990s, this combination has again been advocated to extend the antibacterial spectrum of calcium hydroxide mainly against some facultative or aerobic bacteria (Leonardo *et al.* 1994). Apart from extending the antibacterial spectrum, the combination has a broad antibacterial action and was also effective in eliminating strict and facultative anaerobic bacteria located in dentinal tubules (Siqueira 1996, Siqueira *et al.* 1996, 1997).

Chemically, it has been shown that CMCP plus calcium hydroxide yields calcium *p*-chlorophenolate, a weak salt. In solution with water, the salt takes up the H⁺ ion and goes back into the *p*-chlorophenol, which gives an excess of OH⁻ ions from the water (Anthony *et al.* 1982) thus maintaining the high pH. Leonardo *et al.* (1993c) stated that this formulation prolongs the antibacterial action because of the progressive release of parachlorophenol from the calcium *p*-chlorophenolate complex.

The low liberation of *p*-chlorophenol is probably not high enough to be cytotoxic to the tissues, as demonstrated by Holland *et al.* (1979a) and Leonardo *et al.* (1993b). This absence of cytotoxicity may be because of the small concentration of parachlorophenol released and because, as the high pH causes a superficial proteic denaturation on the tissue it contacts, this may act as a physical barrier to a deeper diffusion of the *p*-chlorophenol into the tissues (Siqueira *et al.* 1996).

Calen + p-chlorophenol. This is the most recent formulation suggested by Leonardo *et al.* (1993c), who demonstrated that camphor is not necessary for the release of Ca²⁺ ions, pH and solubility. Few studies have appeared in the literature. This paste was evaluated for its diffusion through dentine (Leonardo *et al.* 1993a, Esberard *et al.* 1996), and Alencar *et al.* (1997) evaluated the residue of the paste after its use as an intracanal dressing in pulpless dog teeth.

Oily vehicles

Pastes prepared at the time of use

Olive oil. Purified olive oil is a primrose or slightly green coloured liquid with a characteristic odour, which is non-soluble in water but fairly soluble in alcohol. Chemically it is composed of esters of fatty acids such as oleic, linoleic, palmitoleic, stearic and linolenic acids. It must be kept in an amber coloured flask. It promotes low solubility for the calcium hydroxide but improves its physical properties. Because of the low solubility, the paste has a low diffusion within the tissues (Lopes & Costa Filho 1984, Lopes *et al.* 1986, 1996, 1998, Lopes 1987).

Fatty acids. Matsumoto *et al.* (1989) introduced two formulations called New B and New B-2 with a powder:liquid ratio of 1.2 g mL^{-1} . The first formulation has calcium hydroxide powder (100%) and olive oil as the vehicle (100%). New B-2 was composed of calcium hydroxide (65%), bismuth carbonate (15%), resin and zinc oxide (20%), whilst the liquid vehicle was composed of fatty acids (85%) and glycol (15%).

Camphorated parachlorophenol. Camphorated parachlorophenol, or camphorated paramonochlorophenol (CMCP), was introduced by Walkhoff in 1891 (Breillat & Laurichesse 1986). It comprises 33–37% parachlorophenol and 63–67% camphor (United States Pharmacopeia 1989).

Parachlorophenol ($\text{C}_6\text{H}_5\text{OCl}$, molecular weight 128.56) has a characteristic phenolic odour and is presented in crystal form. Camphor ($\text{C}_{10}\text{H}_{16}\text{O}$, molecular weight 152.54) is a cetone obtained from *Cinnamomum camphora* or synthetically in the laboratory; it has a characteristic and penetrating odour, a bitter taste and low solubility in water (United States Pharmacopeia 1989, Lopes *et al.* 1998). The pronounced disinfectant action of parachlorophenol depends on the liberation of the chlorine in the presence of phenol (Breillat & Laurichesse 1986). When camphorated parachlorophenol is the vehicle of a calcium hydroxide paste, it is an oily vehicle because camphor is considered an essential oil with low solubility in water (Lopes *et al.* 1998).

A paste containing the above constituents was introduced by Frank (1964) and Kaiser (1964) and became very popular in the United States after the publication of an article (Frank 1966) describing the

guidelines for apexification procedures in human immature non-vital teeth.

Chemically this paste was evaluated for its pH (Anthony *et al.* 1982, Fuss *et al.* 1996, Peniche *et al.* 1996) and ionic release (Simon *et al.* 1995). Its antibacterial effect was evaluated by Di Fiore *et al.* (1983), Estrela *et al.* (1995a) and Siqueira & Uzeda (1997).

Vital tissue reactions were evaluated when the paste was implanted into rat subcutaneous connective tissue (Souza *et al.* 1977, Mauricio *et al.* 1987), used in apexification procedures in dog (Holland *et al.* 1992) and monkey teeth (Dilewski 1971, Steiner & Van Hassel 1971, Torneck *et al.* 1973) and used as a temporary dressing in non-vital teeth with associated periapical lesions in dog teeth (Holland *et al.* 1979b).

However, it was for apexification procedures in human teeth that this paste was most frequently indicated (Frank 1967, Blanc-Benon 1967, Gloudeman 1968, Steiner *et al.* 1968, Harrison 1969, Van Hassel & Natkin 1969, 1970, Corpron & Dowson 1970, McMillan 1971, Crawford 1972, Feldman *et al.* 1973, Wakai & Naito 1974, Piekoff & Trott 1976, Tenca & Tsamtouris 1978, Ludlow 1979, Levy 1980, Kleier & Barr 1991).

Other clinical situations advocated for the use of this paste are perforation defects after internal resorption (Frank & Weine 1973), reversal of external root resorption (Burke 1976, Montgomery 1984) and as an intracanal dressing in cases of non-vital teeth with associated large periapical lesions (Costa *et al.* 1981, Souza *et al.* 1989).

For a better visualization on radiographs, contrast media such as barium sulphate (Ham *et al.* 1972, Stewart 1975, Arens 1977, Gilbert 1983), iodoform and zinc oxide (Ramos & Bramante 1997) were added.

Metacresylacetate. According to Weiss (1966) this substance was first introduced to dentistry by Coolidge in 1912 for the treatment of necrotic pulps.

Chemically, metacresylacetate is the acetic ester of metacresol in combination with benzene (Spangberg 1994). It is an oily liquid with antibacterial, analgesic and sedative properties (Lecazedieu 1986). Schilder & Amsterdam (1959) showed a minimal inflammatory potential for this substance, whilst Vander Wall *et al.* (1972) showed less cytotoxic activity compared with camphorated parachlorophenol. Its proprietary brand name is Cresatin (Weiss 1966, Stewart 1975, Morse *et al.* 1990, Spangberg 1994).

When calcium hydroxide is mixed with metacresylacetate, a chemical reaction occurs yielding calcium

resinate and acetic acid. The acetic acid suffers an ionic dissociation and gives off H^+ ions, which decreases the pH. In a comparative study, it was shown that this association gave a reduced pH when compared with pastes where calcium hydroxide was mixed with saline or camphorated parachlorophenol (Anthony *et al.* 1982). Its antibacterial effect on *Streptococcus sanguis* has been evaluated by Di Fiore *et al.* (1983).

This paste has been used for pulp capping (Weiss 1966), pulpotomy (Tenca & Tsamtsouris 1978), root-end induction in immature non-vital teeth (Klein & Levy 1974, Levy 1980), retreatment after endodontic and surgical failures (Stewart 1975, West & Lieb 1985) and some types of root resorption (Stewart 1975). For a better radiographic visualization, Stewart (1975) suggested adding barium sulphate in a 1:4 ratio with the calcium hydroxide powder and also suggested preparing a thick paste or a putty consistency because it will not harden, as is the case when calcium hydroxide is mixed with camphorated parachlorophenol.

Eugenol. Eugenol ($C_{10}H_{12}O_2$, molecular weight 164.20) is obtained from oil of cloves and other sources (United States Pharmacopeia 1989). A paste containing calcium hydroxide and eugenol was evaluated for pulpotomy in deciduous dog teeth (Russo & Holland 1974). In humans it has been employed as an intracanal dressing for vital and non-vital deciduous teeth (Murata 1959).

Proprietary brands

Endoapex (Lab. Inodon Ltda. Porto Alegre, RS, Brazil). This paste is composed of calcium hydroxide, liquid silicone and iodoform and was evaluated for apexification of immature dog teeth (Holland *et al.* 1992).

L & C (Herpo Produtos DentArios Ltda., Rio de Janeiro, RJ, Brazil). This paste is the proprietary brand of the paste introduced by Lopes & Costa Filho (1984). The powder is composed of calcium hydroxide (2 g), bismuth carbonate (1 g) and hydrogenized colophony (0.05 g), whilst the liquid is olive oil (0.16 mL).

The paste was evaluated for its ionic dissociation (Marques *et al.* 1994, Esberard *et al.* 1996), apical microleakage (Siqueira & Fraga 1995), after pulpotomy (Bittencourt *et al.* 1997) and in the apexification of immature dog teeth (Silva *et al.* 1991). It was also evaluated for tissue reactions after implantation in rat subcutaneous connective tissue (Motta *et al.* 1997).

In humans it has been used in apexification procedures (Lopes & Costa Filho 1984, Lopes 1987, Lopes *et al.* 1998) and other clinical situations such as resorptions and perforations (Lopes *et al.* 1986).

Vitapex (Neo Dental Chemical Products Co. Ltd, Tokyo, Japan). This paste is very popular in Japan and was introduced by Kawakami *et al.* (1979a,b). It is composed of calcium hydroxide (30.3%), iodoform (40.4%), silicone oil (22.4%) and other substances not described (6.9%).

Since then, a lot of experimental research has been carried out to evaluate the biological behaviour of this paste and its components within the tissues (Kawakami 1984, Kawakami *et al.* 1987a,b,c, 1989, 1990, 1991), as a root canal dressing in non-vital dog teeth (Shibuya 1980) and its effect on apical microleakage (Porkaew *et al.* 1990).

Clinically it was evaluated for healing of periapical tissues when used as an intracanal dressing in human teeth (Eda *et al.* 1985).

Other pastes

Apart from those already reviewed, other pastes have been cited in the literature. A formulation was proposed by Flohr (1936) where calcium hydroxide was mixed with sterilized dentine chips and alkaline blood salts. Another formulation of a paste was composed of calcium hydroxide, methylcresolate and camphorated parachlorophenol (Blanc-Benon 1967).

A paste composed of calcium hydroxide in a 1% aqueous solution of parachlorophenol was suggested by Martins *et al.* (1979), whilst Oletto & Melo (1985) suggested a paste containing a 2% aqueous solution of CMCP. Another suggestion was a paste made with calcium hydroxide and collagen gel, which was evaluated by Pissiotis & Spangberg (1990).

A proprietary brand named Multical composed of calcium hydroxide (34%), barium sulphate (15%) and chloro-timonol (51%) was cited by Webber (1983) and Alliet & Vande Voorde (1988).

Some proprietary brands cited in the literature with neither their formulae nor the names of manufacturers are Hypo-Line (Alliet & Vande Voorde 1988) and Calcipulp (Simpson 1970).

Other proprietary brands discussed in the literature but without descriptive formulae are Dentinigene (Lab. Pierre Rolland, Paris, France) (Castagnola 1956); Biocale (Hammasvaline Oy, Helsinki, Finland) (Rantanen & Louhivuori 1959); DFL calcium

hydroxide (Dental Filling Lab., London, UK) (Souza *et al.* 1977); Carbital (Neo Chemical Products Ltd, Japan) and Caldrium (Opotow Dental Mfg Corp., USA) (Basrani 1983); Octocanal (Lab. Clarben, Madrid, Spain) (Alventosa 1992, Guerrero 1994); Cinacal (Zdravlje, Leskovak, Yugoslavia) (Tamburic *et al.* 1993); Hydrocalcium (Société Endo Technologique, Marseille, France) (Fuss *et al.* 1996); and Rootcal (Ellman International Inc., Hewlett, NY, USA) (Rehman *et al.* 1996).

Calcium hydroxide and other substances

Radiographic contrast media

Calcium hydroxide mixed with any of the quoted vehicles lacks radiopacity and is not easily seen radiographically. This is the main reason radiopaque materials are added to the paste, thereby allowing identification of lateral and accessory canals, resorptive defects, fractures and other structures (Smith & Woods 1983, Alaçam *et al.* 1990). A radiopacifier should have an atomic weight higher than calcium for radiopacity purposes (Tavano *et al.* 1978). Some examples of such substances are barium sulphate and bismuth, and other compounds containing iodine and bromine (Alaçam *et al.* 1990).

As bismuth salts have some degree of toxicity and soluble barium salts are extremely toxic materials and relatively insoluble, the actual alternative is to use a more soluble radiopaque substance. Tavano *et al.* (1978) stated that there are three types of iodine compounds: soluble iodine organic substances, non-soluble iodine oils and slowly absorbable iodine oils.

When mixed with calcium hydroxide powder, these substances will become the vehicle of the paste as well as being the radiopaque agent. Holland *et al.* (1983) compared Telebrix (an aqueous vehicle) with Lipiodol (an oily vehicle) as vehicles in two calcium hydroxide pastes and obtained better results with Lipiodol. Two other studies have appeared in the Brazilian literature using these types of vehicles. Mauricio *et al.* (1987) tested the same paste suggested by Holland *et al.* (1983) (calcium hydroxide + Lipiodol), whilst Cesar *et al.* (1985) tested a paste composed of calcium hydroxide (2 g), barium sulphate (0.5 g), hydrogenized colophony (0.05 g) and Lipiodol as the vehicle. Both studies were performed in animals and no studies have evaluated these suggested formulations in humans.

Smith & Woods (1983) tested a calcium hydroxide–diatrizoate paste. Diatrizoates are substances that have

been used previously to aid in the diagnosis of periapical lesions (Forsberg & Hagglund 1960, Cunningham & Penick 1968) and to elucidate the pathways of anaesthetic injections (Berns & Sadove 1962, Galbreath 1970). A commercially available soluble iodine compound (Renograffing) containing aqueous solutions of 66% diatrizoate meglumine and 10% sodium diatrizoate was mixed with calcium hydroxide powder and compared with a barium sulphate–calcium hydroxide paste. The diatrizoate–calcium hydroxide paste was more manageable, successfully induced apical closure in a non-vital traumatized maxillary central incisor and did not obscure the apical radiographic evaluation.

Some time later, Alaçam *et al.* (1990) tested another organic iodine compound, iothalamate. This substance is soluble in water, clear and colourless to pale yellow in colour, slightly viscous in consistency and has been used in diagnostic urography, angiography and venography. A iothalamate–calcium hydroxide paste showed similar results when compared with a diatrizoate–calcium hydroxide paste and these two iodine organic compounds can be used as alternatives to barium sulphate and other radiopacifiers.

Corticosteroid-antibiotic solutions

The use of corticosteroids to reduce inflammation and maintain the vitality and integrity of the injured pulp tissue is an established procedure (Fiore-Donno & Baume 1962, Lawson & Mitchell 1964). As calcium hydroxide has been proved to offer better clinical results, some attempts have been made to mix these two substances and evaluate these formulations for endodontic purposes in vital pulp therapy, such as in direct pulp capping and pulpotomy procedures.

Bhaskar *et al.* (1969) mixed 0.03 mL of Metimyd (prednisolone-sulphacetamide with neomycin) with calcium hydroxide and this was implanted in the abdominal wall of male albino rats. After 12–20 days they concluded that the paste reduced the intensity and duration of oedema, reduced the intensity of the cellular infiltrate, markedly reduced or eliminated tissue necrosis and markedly reduced or eliminated the dystrophic calcification of tissue.

Otosporin is a corticosteroid–antibiotic solution composed of polymixin B sulphate (10 000 IU), neomycin (5 mg) and hydrocortisone (10 mg) in an aqueous vehicle and has been shown to maintain the integrity of the pulp stump as an interappointment dressing in vital pulpectomy in dog teeth (Holland *et al.*

1971) and gave favourable results in humans with regard to postoperative pain after pulpectomies (Fava 1992). Holland (1994) has proposed mixing calcium hydroxide powder with Otosporin.

A very popular formulation is a paste composed of a mixture of calcium hydroxide and Ledermix (Lederle Lab.). This anti-inflammatory-antibiotic compound has triamcinolone acetonide and demethylchlorotetracycline calcium and was chemically evaluated for its ionic diffusion by Abbott *et al.* (1989) and clinically evaluated in direct pulp capping, pulpotomy, routine intracanal dressing and apexification procedures (Eguren 1971, Schroeder 1981) and in the treatment of large periapical lesions (Heithersay 1985). Ledermix was also mixed with Calnex and evaluated for long-term prognosis after human pulpotomy (Santini 1985, 1986).

Antibiotics

The use of calcium hydroxide-antibiotic pastes has been suggested and these have been tested in laboratory studies, but no clinical studies are forthcoming.

Quillin *et al.* (1992) suggested adding metronidazole and chlorhexidine to a calcium hydroxide paste and tested this formulation for its antibacterial effect. Another association was proposed by Antoniazzi & Marques and cited by Takeuti *et al.* (1997), which involved mixing calcium hydroxide (0.13 g), metronidazole (0.6 g), ciprofloxacin (0.6 g) and polyethylene-glycol 1000.

Conclusions

The vehicle to which calcium hydroxide is mixed to form the paste used in endodontics affects the physical and chemical properties of the compound and hence its clinical applications. In general, viscous and oily vehicles prolong the action of the calcium hydroxide compared with water-soluble substances.

References

- Abbott PV, Hume WR, Heithersay GS (1989) Effects of combining Ledermix® and calcium hydroxide pastes on the diffusion of corticosteroid and tetracycline through human roots in vitro. *Endodontics and Dental Traumatology* **5**, 188–92.
- Acosta EMC, Heredia AC (1986) Biopulpectomia cameral al hidroxido de calcio. Estudio preliminar. *Revista de Actualidad Estomatológica Española* **46**, 33–40.
- Alaçam T, Gorgul G, Omurlu H (1990) Evaluation of diagnostic radiopaque contrast materials used with calcium hydroxide. *Journal of Endodontics* **16**, 365–8.
- Alencar AHG, Leonardo MR, Silva LAB, Silva RS, Ito IY (1997) Determination of the p-monochlorophenol residue in the calcium hydroxide + p-monochlorophenol combination used as an intracanal dressing in pulpless teeth of dogs with induced chroni. *Journal of Endodontics* **23**, 522–4.
- Allard U, Stromberg U, Stromberg T (1987) Endodontic treatment of experimentally induced apical periodontitis in dogs. *Endodontics and Dental Traumatology* **3**, 240–4.
- Alliet P, Vande Voorde H (1988) Le rôle de l'hydroxyde de calcium en Endodontie. *Revue Belge de Médecine Dentaire* **43**, 24–39.
- Alventosa C (1992) Apicoformación: tratamiento del diente inmaduro. *Endodoncia* **10**, 176–85.
- Andersen M, Lund A, Andreassen JO, Andreassen AI (1992) In vitro solubility of human pulp tissue in calcium hydroxide and sodium hypochlorite. *Endodontics and Dental Traumatology* **8**, 104–8.
- Andrioni JN, Russo MC (1974) Evaluation of vital and devitalizing methods for pulpotomy in deciduous teeth. *Revista da Faculdade de Odontologia de Araçatuba* **3**, 291–301.
- Anthony JR (1986) Apexification during active orthodontic movement. *Journal of Endodontics* **12**, 419–21.
- Anthony DR, Gordon TX, del Rio CE (1982) The effect of three vehicles on the pH of calcium hydroxide. *Oral Surgery, Oral Medicine and Oral Pathology* **54**, 560–5.
- Anthony DR, Senia ES (1981) The use of calcium hydroxide as a temporary paste fill. *Texas Dental Journal* **99**, 6–10.
- Arens D (1977) Treatment of the incompletely formed teeth. *Journal of the Indiana Dental Association* **56**, 15–20.
- Armstrong WP, Hoffman S (1962) Pulp-cap study. *Oral Surgery, Oral Medicine and Oral Pathology* **15**, 1505–9.
- Asai Y, Ishikawa T, Machida Y (1981) Clinico-pathological investigation on the healing effects of modified Calvital to the exposed human pulp wounds. *Japanese Journal of Conservative Dentistry* **24**, 271–81.
- Asano S, Ishikawa T, Sekine N (1974) Clinico-pathological study of direct pulp capping and immediate root canal filling after vital pulp extirpation with N₂ and Calvital. *Bulletin of the Tokyo Dental College* **15**, 161–80.
- Assed S, Leonardo MR, Silva UW, Ito YI (1996) Prevalência de microrganismos em canais radiculares de dentes com necrose pulpar e reação periapical crônica. Imunofluorescência indireta – efeito do preparo biomecânico e do curativo de demora pela cultura. *Revista Brasileira de Odontologia* **53**, 24–8.
- Badillo F, Elbaun R, Brouillet SL (1985) L'hydroxyde de calcium en thérapeutique endocanalaire. *Revue Française D'Endodontie* **4**, 79–89.
- Bairy I, Bhat KS, Shivananda PG (1993) An *in vitro* evaluation of antibacterial actions of calcium hydroxide

- against causative microorganisms of osteomyelitis. *Indian Journal of Medical Microbiology* **11**, 238–42.
- Balcow WN, Martindale W (1972) *The Extra Pharmacopeia*, 26th edn. London: Pharmaceutical Press.
- Barbosa CAM, Gonçalves RB, Siqueira JF Jr, Uzeda M (1995) Evaluation of the antibacterial activities of calcium hydroxide, chlorhexidine and camphorated paramonochlorophenol as intracanal medicaments. A clinical and laboratory study. *Journal of Endodontics* **23**, 297–300.
- Barbosa SV, Spangberg LSW, Almcida D (1994) Low surface tension calcium hydroxide solution is an effective antiseptic. *International Endodontic Journal* **27**, 6–10.
- Barclay C (1993) Root resorption. 2 – internal root resorption. *Dental Update* **20**, 292–4.
- Basrani E (1983) *Fracturas Dentárias. Prevención y Tratamiento de la Vulva Vital y Mortificada*. Buenos Aires: Intermédica.
- Bellacosa S, Archilla JRF, Marques JLSL, Bombana AC (1993) Conduta endodôntica em dentes com reabsorção externa/interna: utilização de gutapercha termo-plastificada (sistema Ultrafill). *Revista da Associação Paulista de Cirurgiões Dentistas* **47**, 965–8.
- Beltes P, Pissiotis E, Koulaouzidou E, Kortsaris AH (1997) In vitro release of hydroxyl ions from six types of calcium hydroxide non-setting pastes. *Journal of Endodontics* **23**, 413–5.
- Berbert A (1978) *Comportamento dos tecidos apicais e periapicais após biopulpectomia e obturação do canal com AH-26, hidróxido de cálcio ou mistura de ambos. Estudo histológico em dentes de cães* (Thesis). Baurú.
- Berck H (1950) The effect of calcium hydroxide-methylcellulose paste on the dental pulp. *Journal of Dentistry for Children* **17**, 65–8.
- Berck H (1957) Preservation of the dental pulp in deep seated cavities. *Journal of the American Dental Association* **54**, 226–33.
- Berns JM, Sadove MS (1962) Mandibular block injection: a method of study using an injected radiopaque material. *Journal of the American Dental Association* **65**, 735–45.
- Bhaskar SN, Cutright DE, Van Osdel V (1969) Tissue response to cortisone containing and cortisone free calcium hydroxide. *Journal of Dentistry for Children* **36**, 193–8.
- Bhat KS, Walkevar S (1975) Evaluation of bactericidal property of propylene glycol for its possible use in endodontics. *Journal of the Healthy Science (Arogya)* **1**, 54–9.
- Bieberfeld RC, Taintor JF (1980) Root end closure in adults: report of cases. *Journal of Endodontics* **6**, 691–5.
- Binnie WH, Rowe AHR (1973) A histological study of the periapical tissues of completely formed pulpless teeth filled with calcium hydroxide. *Journal of Dental Research* **52**, 1110–6.
- Bittencourt AZ, Mallmann J, Rezende EV (1997) Comportamento da polpa após pulpotomia e recobrimento com materiais à base de hidróxido de cálcio e de óxido de zinco e eugenol. *Revista Brasileira de Odontologia* **54**, 138–42.
- Blanc-Benon M (1967) Traitement des dents permanentes infectées à apex largement ouvert. *Annales Odontostomatologiques de Lyon* **24**, 75–80.
- Bogaerts P (1997) Treatment of root perforations with calcium hydroxide and Super EBA cement: a clinical report. *International Endodontic Journal* **30**, 210–9.
- Breillat J, Brocheriou C, Machtou P (1983a) Le traitement endodontique des dents permanentes immatures. 1 – Apexogenèse. *Revue Française d'Endodontie* **2**, 11–28.
- Breillat J, Brocheriou C, Machtou P (1983b) Le traitement endodontique des dents permanentes immatures. 2 – Apexification. *Revue Française d'Endodontie* **2**, 11–29.
- Breillat J, Laurichesse J-M (1986) Traitements endodontiques des dents permanentes immatures. In: Laurichesse J-M, Maestroni F, Breillat J. *Endodontie Clinique*. Paris: Éditions CDP.
- Bremer K (1980) Antibakterielle Wirksamkeit von Calciumhydroxid in Abhängigkeit vom Alter des Präparates. *Quintessenz* **38**, 1275–80.
- Burke JH (1976) Reversal of external root resorption. *Journal of Endodontics* **2**, 87–8.
- Bystrom A, Claesson R, Sundqvist G (1985) The antibacterial effect of camphorated paramonochlorophenol, camphorated phenol and calcium hydroxide in the treatment infected root canals. *Endodontics and Dental Traumatology* **1**, 170–5.
- Çalışkan MK, Pehlivan Y (1996) Prognosis of root-fractured permanent incisors. *Endodontics and Dental Traumatology* **12**, 129–36.
- Çalışkan MK, Sen BH (1996) Endodontic treatment of teeth with apical periodontitis using calcium hydroxide: a long term study. *Endodontics and Dental Traumatology* **12**, 215–21.
- Çalışkan MK, Sen BH, Ozinel BH (1994) Treatment of extra oral sinus tracts from traumatized teeth with apical periodontitis. *Endodontics and Dental Traumatology* **10**, 115–20.
- Çalışkan MK, Turkun M (1996) Root canal treatment of a root-fractured incisor tooth with internal resorption: a case report. *International Endodontic Journal* **29**, 393–7.
- Çalışkan MK, Turkun M (1997) Prognosis of permanent teeth with internal resorption: a clinical review. *Endodontics and Dental Traumatology* **13**, 75–81.
- Caputo CA (1997) *Avilação 'in vitro' da variação do pH de uma solução aquosa diante da imersão de dentes humanos parcialmente impermeabilizados e portadores de curativo oclusivo de hidróxido de cálcio, tendo como fonte de variação o veículo da medicação intracanal* (Thesis). São Bernardo do Campo.
- Castagnola L (1956) *La Conservación de la Vitalidad de la Pulpa*. Buenos Aires: Mundi.
- Cesar CAS, Leonardo NIR, Lia RCC, Benatti Neto C (1985) Estudo comparativo da resposta do tecido conjuntivo subcutâneo do rato ao implante de tubos de dentina obturados parcialmente e completados com diferentes misturas de hidróxido de cálcio. *Revista de Odontologia da UNESP* **14**, 47–58.

- Chosak A, Sela J, Cleaton-Jones P (1997) A histological and quantitative histomorphometric study of apexification of nonvital permanent incisors of vervet monkeys after repeated root filling with a calcium hydroxide paste. *Endodontics and Dental Traumatology* **13**, 211–7.
- Citrome GP, Kaminski EJ, Heuer MA (1979) A comparative study of tooth apexification in the dog. *Journal of Endodontics* **5**, 290–7.
- Codman WW (1851) Ossification of the pulp of a tooth. *Newsletter* **IV**, 90 (printed in Malo PRT, Kessler Nieto F, Vadillo MVM (1987) Hidróxido de calcio y apicoformación. *Revista Española de Endodoncia* **5**, 41–61).
- Conrado CA, Finn SD, Winkler CH (1965) Considerações sobre o pH do hidróxido de calcio em Endodontia. *Revista Brasileira de Odontologia* **24**, 56–61.
- Corpron RE, Dowson J (1970) Pulpal therapy for the traumatized immature permanent anterior teeth. *Journal of the Michigan Dental Association* **50**, 224–30.
- Costa AD, Anzai A, Burati Neto J, Ikeda J (1981) Uso do hidróxido de calcio, no tratamento de dentes com lesões periapicais. Relato clínico de 13 casos. *Revista da Associação Paulista de Cirurgiões Dentistas* **35**, 220–6.
- Crabb HSM (1965) The basis of root canal therapy. *Dental Practitioner and Dental Record* **15**, 397–401.
- Crawford FC II (1972) Another contraindication for odontectomy: endodontics for the wide open apex in maxillary second molars. *Journal of the California Dental Association* **48**, 22–4.
- Cunningham CJ, Penick EC (1968) Use of a roentgenographic contrast medium in the differential diagnosis of periapical lesions. *Oral Surgery, Oral Medicine and Oral Pathology* **26**, 96–102.
- Cvek M (1972) Treatment of non-vital permanent incisors with calcium hydroxide I – Follow-up of periapical repair and apical closure of immature roots. *Odontologisk Revy* **23**, 27–44.
- Cvek M (1973) Treatment of non-vital permanent incisors with calcium hydroxide. II – Effect on external root resorption in luxated teeth compared with effect of root filling with gutta-percha. A follow-up. *Odontologisk Revy* **24**, 343–54.
- Cvek M (1974) Treatment of non-vital permanent incisors with calcium hydroxide. IV – Periodontal healing and closure of the root canal in the coronal fragment of teeth with intra-alveolar fracture and vital apical fragment. *Odontologisk Revy* **25**, 239–46.
- Cvek M (1976) Treatment of non-vital permanent incisors with calcium hydroxide. VI – A clinical, microbiological and radiological evaluation of treatment in one sitting of teeth with mature or immature root. *Odontologisk Revy* **2**, 93–108.
- Cvek M (1989) *Calcium Hydroxide in the Treatment of Traumatized Teeth*. Stockholm: Eastman Institute.
- Cvek M (1992) Prognosis of luxated non-vital maxillary incisors treated with calcium hydroxide and filled with gutta-percha. A retrospective clinical study. *Endodontics and Dental Traumatology* **8**, 45–55.
- Cvek M, Sundstrom B (1974) Treatment of non-vital permanent incisors with calcium hydroxide. V – Histologic appearance of roentgenographically demonstrable apical closure of immature roots. *Odontologisk Revy* **25**, 379–91.
- Danin J, Stromberg T, Forsgren H, Linder LE, Ramskold LO (1996) Clinical management of nonhealing periradicular pathosis. *Oral Surgery, Oral Medicine and Oral Pathology* **82**, 213–7.
- Deardorf KA, Swartz MI, Newton CW, Brown CE Jr (1994) Effect of root canal treatments on dentin permeability. *Journal of Endodontics* **20**, 1–5.
- Deveaux E, Deveaux B, Dufour-Tryhoen V (1986) Le coiffage pulpaire direct. *Revue Française d'Endodontie* **5**, 61–73.
- Di Fiore PM, Peters DD, Setterstrom JÁ, Lorton L (1983) The antibacterial effects of calcium hydroxide apexification pastes on *Streptococcus sanguis*. *Oral Surgery, Oral Medicine and Oral Pathology* **55**, 91–4.
- Dilewski JJ (1971) Apical closure of non-vital teeth. *Oral Surgery, Oral Medicine and Oral Pathology* **32**, 82–9.
- Dumsha TC, Gutmann M (1985) Clinical techniques for the placement of calcium hydroxide. *Compendium of Continuing Education in Dentistry* **6**, 482–9.
- Eda S, Kawakami T, Hasegawa H, Watanabe I, Kato K (1985) Clinico-pathological studies on the healing of periapical tissues in aged patients by root canal filling using pastes of calcium hydroxide added iodoform. *Gerodontics* **1**, 98–104.
- Eguren AEO (1971) Vers la fermeture biologique du foramen apical en Endodontie. *Revue du Stomatologie et Chirurgie Maxillo-Faciale* **72**, 310–3.
- Ehrmann EH, Geurtsen W (1985) Die apexifikation von marktoten Zähnen ohne abgeschlossenes Wurzelwachstum. *Deutsche Zahnärztliche Zeitschrift* **10**, 986–92.
- Engstrom B, Spangberg L (1967) Wound healing after partial pulpectomy. A histological study performed in contralateral pairs. *Odontologisk Revy* **75**, 5–18.
- Erdogan G (1997) The treatment of non-vital immature teeth with calcium hydroxide-sterile water paste. Two case reports. *Quintessence International* **28**, 681–6.
- Esberard RM (1992) Reparação apical e periapical pós tratamento endodôntico nos dentes de cães portadores de lesões periapicais induzidas. Influência da técnica. Estudo radiográfico e microscópico (Thesis). Araraquara.
- Esberard RM, Carnes DL Jr, del Rio CE (1996) Reabsorção radicular. Influência de diferentes tipos de pastas de hidróxido de calcio na mudança do pH da superfície radicular. *RGO* **44**, 267–70.
- Estrela C (1994) *Análise química de pastas de hidróxido de calcio frente à liberação de ions calcio, de ions hidroxila e formação de carbonato de calcio na presença de tecido con i untivo de cão* (Thesis). São Paulo.
- Estrela C, Bammann LL, Sydney GB, Moura J (1995a) Efeito antibacteriano de pastas de hidróxido de calcio sobre bactérias anaeróbias facultativas. *Revista da Faculdade de Odontologia de Baurú* **3**, 21–6.

- Estrela C, Pesce HF (1996) Chemical analysis of the liberation of calcium and hydroxyl ions from calcium hydroxide pastes in connective tissue in the dog. Part I. *Brazilian Dental Journal* **7**, 41–6.
- Estrela C, Sydney GB, Pesce HF, Felipe O Jr (1995b) Dentinal diffusion of hydroxyl ions of various calcium hydroxide pastes. *Brazilian Dental Journal* **6**, 5–9.
- Fava LRG (1991) Pastas de hidróxido de calcio. Considerações sobre seu emprego clínico em Endodontia. *Revista Paulista de Odontologia* **13**, 36–43.
- Fava LRG (1992) Human pulpectomy: incidence of postoperative pain using two different intracanal dressings. *International Endodontic Journal* **25**, 257–60.
- Fava LRG (1994) A clinical evaluation of one- and two-appointment root canal therapy using calcium hydroxide. *International Endodontic Journal* **27**, 47–51.
- Fava LRG (1996) Retratamento endodôntico após fracasso endodôntico e cirúrgico. *Jornal da Associação Paulista de Cirurgiões Dentistas Vila Mariana* **4**, 6–9.
- Fava LRG (1998) Acute apical periodontitis: incidence of postoperative pain using two different root canal dressings. *International Endodontic Journal* **31**, 343–7.
- Feiglin B (1985) Differences on apex formation during apexification with calcium hydroxide paste. *Endodontics and Dental Traumatology* **1**, 195–9.
- Feldman G, Solomon C, Notaro P, Moskowitz E (1973) Endodontic treatment of vital and non-vital teeth with open apex. *New York State Dental Journal* **39**, 277–80.
- Felippe MCS (1998) *Estudo 'in vitro' do transporte de ions hidroxila e calcio através da dentina radicular* (Thesis). Florianópolis.
- Fiore-Donno G, Baume LJ (1962) Effects of capping compounds containing corticosteroids on the human dental pulp. *Helvetica Odontologica Acta* **6**, 23–32.
- Flohr W (1936) Die biologische Wurzelbehandlung. *Zahnärztliche Rundschau* **31** (also in: Castagnola L (1956) *La Conservación de la Vitalidad de la Pulpa*. Buenos Aires: Mundi).
- Foreman PC, Barnes IE (1990) A review of calcium hydroxide. *International Endodontic Journal* **23**, 283–97.
- Forsberg A, Hagglund G (1960) Differential diagnosis of radicular cyst and granuloma. Use of X-ray contrast medium. *Dental Radiograph and Photograph* **33**, 84–8.
- Fortier TP, Aldin P, Villete F, Migraine D (1991) Traumatismes des incisives permanentes de l'enfant et l'adolescent. Les sequelles pulpaires. *Le Chirurgien-Dentiste de France* **61**, 69–82.
- Foster KH, Kulild JC, Weller RN (1993) Effect of smear layer removal on the diffusion of calcium hydroxide through radicular dentin. *Journal of Endodontics* **19**, 136–40.
- Foster KH, Primack PD, Kulild JC (1992) Odontogenic cutaneous sinus tract. *Journal of Endodontics* **18**, 304–6.
- Frank AL (1964) Experimental efforts to effect a closing of the wide open pulpless tooth allowing conservative therapy rather than surgical intervention. *Twenty-first Annual Meeting of the American Association of Endodontics*. USA: Washington, DC.
- Frank AL (1966) Therapy for the divergent pulpless tooth by continuing apical formation. *Journal of the American Dental Association* **72**, 87–93.
- Frank AL (1967) Endodontic endosseous implants and treatment of the wide open apex. *Dental Clinics of North America* **November**, 675–700.
- Frank AL, Weine FS (1973) Nonsurgical therapy for the perforative defect of internal resorption. *Journal of the American Dental Association* **87**, 863–8.
- Freitas JF (1982) Characterization and aqueous extraction of calcium hydroxide compounds. *Australian Dental Journal* **2**, 352–6.
- Fuss Z, Rafaeloff R, Tagger M, Szajkis S (1996) Intracanal pH changes of calcium hydroxide pastes exposed to carbon dioxide in vitro. *Journal of Endodontics* **22**, 362–4.
- Galbreath JC (1970) Tracing the course of the mandibular block injection. *Oral Surgery, Oral Medicine and Oral Pathology* **30**, 571–82.
- Gallagher CS, Mourino AP (1979) Root-end induction. *Journal of the American Dental Association* **98**, 578–80.
- Garcia GH (1983) Bosquejo historico sobre Endodoncia. *Revista Española de Endodoncia* **1**, 123–33.
- Ghose U, Baghdady VS, Hykmat BYM (1987) Apexification on immature apices of pulpless permanent anterior teeth with calcium hydroxide. *Journal of Endodontics* **13**, 285–90.
- Gilbert B (1983) Endodontic treatment of the open apex. *Quintessence International* **3**, 293–9.
- Gimlin DR, Schindler WG (1990) The management of postbleaching cervical resorption. *Journal of Endodontics* **16**, 292–7.
- Girard C, Holz J (1985) Contrôles à court et à long termes du traitement de la catégorie IV des pulpopathies à l'aide d'hydroxyde de calcium. *Schweizerische Monatsschrift für Zahnmedizin* **95**, 169–82.
- Giro EMA, Iost HI, Lia RCC (1993) Análise histopatológica comparativa em polpa de dentes de cães após pulpotomia e utilização de pastas à base de hidróxido de calcio em diferentes veículos. *Anais da Sociedade Brasileira de Pesquisas Odontológicas* **9**, 66 (Abstract).
- Gloudeman EA (1968) Endodontic management of the wide open apex. *Journal of the Wisconsin State Dental Society* **44**, 49–53.
- Goldberg F (1982) Materiales y técnicas de obturación endodôntica. Buenos Aires: Mundi.
- Goldman M (1974) Root-end closure techniques including apexification. *Dental Clinics of North America* **18**, 297–308.
- Gomes TC, Chevitarese O, Almcida NS, Salles MR, Gomes GC (1996) Diffusion of calcium through dentine. *Journal of Endodontics* **22**, 590–5.
- Granath L-E (1959) Nagra synpunkter pa behandlingen av traumatiserade incisiver pabarn. *Odontologisk Revy* **10**, 272–86.

- Gregoriou AP, Jeansonne BG, Musselman W (1994) Timing of calcium hydroxide therapy in the treatment of root resorption in replanted teeth of dogs. *Endodontics and Dental Traumatology* **10**, 268–75.
- Guerrero FF (1994) Tratamiento de conductos en un molar inferior com apices inmaturos. *Endodoncia* **12**, 203–9.
- Guigand M, Vulcain J-M, Dantel-Morazin A, Bonnaure-Mallet M (1997) In vitro study of intradental calcium diffusion induced by two endodontic, biomaterials. *Journal of Endodontics* **23**, 387–90.
- Guignes P, Burnel F, Maurette A (1991) Élimination de deux présentations d'hydroxyde de calcium: étude au M.E.B. *Revue Française d'Endodontie* **10**, 29–35.
- Gutmann JL, Fava LRG (1992) Periradicular healing and apical closure of a non-vital tooth in the presence of apical contamination. *International Endodontic Journal* **25**, 307–11.
- Ham JW, Patterson SS, Mitchell DF (1972) Induced apical closure of immature pulpless teeth in monkeys. *Oral Surgery, Oral Medicine and Oral Pathology* **33**, 438–49.
- Harrison LM (1969) Continued apical formation in the immature non-vital teeth. *Journal of the Louisiana Dental Association* **27**, 6–9.
- Harrison JW, Rakusin H (1985) Intracanal cementosis following induced apical closure. *Endodontics and Dental Traumatology* **1**, 242–5.
- Hasselgren G, Olsson B, Cvek M (1988) Effects of calcium hydroxide and sodium hypochlorite on the dissolution of necrotic porcine muscle tissue. *Journal of Endodontics* **14**, 125–7.
- Heithersay GS (1970a) Periapical repair following conservative endodontic therapy. *Australian Dental Journal* **15**, 511–8.
- Heithersay GS (1970b) Stimulation of root formation in incompletely developed pulpless teeth. *Oral Surgery, Oral Medicine and Oral Pathology* **29**, 620–30.
- Heithersay GS (1975) Calcium hydroxide in the treatment of pulpless teeth with associated pathology. *Journal of the British Endodontic Society* **8**, 74–98.
- Heithersay GS (1985) Clinical endodontic and surgical management of tooth with associated bone resorption. *International Endodontic Journal* **18**, 72–92.
- Hermann BW (1920) Calcium hydroxyd als mitten zum behandeln und füllen von Wurzelkanällen (dissertation). Wursburg: (printed in: Malo PRT, Kessler Nieto F, Vadillo MVM (1987) Hidroxido de calcio y apicoformación. *Revista Española de Endodoncia* **5**, 41–61).
- Hermann BW (1930) Dentinobliteration der Würzelkanällen nach Behandlung mit Kalzium. *Zahnärztliche Rundschau* **21**, 888–99.
- Hermann BW (1935a) Die biologische wurzelbehandlung. *Zahnärztliche Rundschau* **44**, 1509–17.
- Hermann BW (1935b) Der desinfektorische Wert des Calxyl. *Zahnärztliche Rundschau* **44**, 1929–34.
- Hermann BW (1935c) Die Kalziumkomponente in der Wurzelbehandlung. *Deutsche Zahnärztliches Wochenschrift* **38**, 461–5.
- Hermann BW (1936) *Biologische Wurzelbehandlung*. Frankfurt am Main: W. Kramer.
- Hess W (1950) The treatment of teeth with exposed healthy pulps. *International Dental Journal* **1**, 10–35.
- Holland R (1994) Emprego tópico de medicamentos no interior dos canais radiculares. *Odontomaster* **1**, 1–13.
- Holland R, Maisto AO, Souza V, Maresca BM, Nery W (1981) Acción y velocidad de reabsorción de distintos materiales de obturación de conductos radiculares en el tejido conectivo periapical. *Revista de la Asociación Odontológica Argentina* **69**, 7–17.
- Holland R, Pinheiro CE, Mello W, Nery W, Souza V (1982) Histochemical analysis of the dog's dental pulp after pulp capping with calcium, barium and strontium hydroxides. *Journal of Endodontics* **8**, 444–7.
- Holland R, Souza V, Mello W, Nery MJ, Bernabé PFE, Otoboni Filho JA (1980a) Healing process of dog's dental pulp after pulpotomy and protection with calcium hydroxide. *Revista de Odontologia da UNESP* **8/9**, 67–73.
- Holland R, Souza V, Nery MJ, Bemabé PFE, Mello W, Otoboni Filho JA (1978a) The effect of calcium hydroxide in dentine. *Revista da Faculdade de Odontologia de Araçatuba* **7**, 177–83.
- Holland R, Souza V, Nery MJ, Bernabé PFE, Mello W (1975) *Endodontia* (Apostil). Araçatuba: Faculdade de Odontologia de Araçatuba.
- Holland R, Souza V, Nery MJ, Bernabé PFE, Mello W, Otoboni Filho JA (1979a) *Endodontia* (Apostil). Araçatuba: Faculdade de Odontologia de Araçatuba.
- Holland R, Souza V, Nery MJ, Bernabé PFE, Mello W, Otoboni Filho JA (1992) Comportamento dos tecidos periapicais de dentes de cães com rizogênese incompleta após obturação do canal com diferentes materiais obturadores. *Revista Brasileira de Odontologia* **49**, 49–53.
- Holland R, Souza V, Nery MJ, Mello W, Bernabé PFE (1979b) A histological study of the effect of calcium hydroxide in the treatment of pulpless teeth of dogs. *Journal of the British Endodontic Society* **12**, 15–23.
- Holland R, Souza V, Nery MJ, Mello W, Bernabé PFE (1983) Root canal treatment with calcium hydroxide. Effect of an oily or a water soluble vehicle. *Revista de Odontologia da UNESP* **12**, 1–6.
- Holland R, Souza V, Nery MJ, Mello MJ, Bernabé PFE, Otoboni Filho JA (1978b) Effect of the dressing in root canal treatment with calcium hydroxide. *Revista da Faculdade de Odontologia de Araçatuba* **7**, 40–5.
- Holland R, Souza V, Nery MJ, Mello W, Bernabé PFE, Otoboni Filho JA (1978c) Root canal treatment of pulpless teeth with Calvital or zinc oxide-eugenol in one or two sittings. Histological study in dogs. *Revista da Faculdade de Odontologia de Araçatuba* **7**, 47–53.
- Holland R, Souza V, Nery MJ, Mello W, Bernabé PFE, Otoboni

- Filho JA (1980b) Emprego, da associação corticosteróide-antibiótico durante o tratamento endodôntico. *Revista Paulista de Endodontia* **2**, 4–7.
- Holland R, Souza V, Russo MC (1973) Healing process after root canal therapy in immature human teeth. *Revista da Faculdade de Odontologia de Araçatuba* **2**, 269–73.
- Holland R, Souza V, Tagliavini RL, Milanezi LA (1971) Healing process of teeth with open apex: histological study. *Bulletin of the Tokyo Dental College* **12**, 333–8.
- Horsted P, Sendergaard B, Thylstrup A, El Attar K, Fejerskov O (1985) A retrospective study of direct pulp capping with calcium hydroxide compounds. *Endodontics and Dental Traumatology* **1**, 29–34.
- Hussey DL, Kennedy JG (1990) Conservative treatment of a large radiolucent cyst-like apical lesion – a case report. *Restorative Dentistry* **6**, 12–3.
- Ida K, Maseki T, Yamasaki M, Hirano S, Nakamura H (1989) The pH values of pulp-capping agents. *Journal of Endodontics* **15**, 365–8.
- Imanishi T (1980) A clinico-pathological study of pulpotomy on deciduous teeth. *Journal of the Tokyo Dental College Society* **72**, 647–94.
- Juge H (1959) Resorbable pastes for root filling. *International Dental Journal* **9**, 461–76.
- Kaiser HJ (1964) Management of the wide open apex with calcium hydroxide compounds. *Twenty-First Annual Meeting of the American Association of Endodontics*. USA: Washington DC.
- Kawakami T (1984) An experimental study on tissue reaction to a paste made of calcium hydroxide and iodoform with an addition of silicone oil. *Journal of the Tokyo Dental College Society* **84**, 77–107.
- Kawakami T, Nakamura C, Eda S (1991) Effects of the penetration of a root canal filling material into the mandibular canal. I – Tissue reactions to the material. *Endodontics and Dental Traumatology* **7**, 36–41.
- Kawakami T, Nakamura C, Hasegawa H, Akahane S, Eda S (1987c) Ultrastructural study of initial calcification in the rat subcutaneous tissues elicited by a root canal filling material. *Oral Surgery, Oral Medicine and Oral Pathology* **63**, 360–5.
- Kawakami T, Nakamura C, Hasegawa H, Eda S (1987a) Fate of ⁴⁵Ca labeled calcium hydroxide in a root canal filling paste embedded in rat subcutaneous tissue. *Journal of Endodontics* **13**, 220–3.
- Kawakami T, Nakamura C, Hasegawa H, Eda S (1987b) Fate of ¹⁴C-labeled dimethylpolysiloxane (silicone oil) in a root canal filling material embedded in rat subcutaneous tissues. *Dental Materials* **3**, 256–60.
- Kawakami T, Nakamura C, Hayashi T, Eda S (1979b) Studies on tissue reactions to the paste of calcium hydroxide added iodoform (root canal filling material: Vitapex[®]). Second report: an electron microscopic study. *Matsumoto Shigaku* **5**, 161–70.
- Kawakami T, Nakamura C, Hayashi T, Eda S, Akahane S (1979a) Studies on the tissue reactions to the paste of calcium hydroxide added iodoform (root canal filling material: Vitapex[®]). First report: a histopathological study. *Matsumoto Shigaku* **5**, 35–44.
- Kawakami T, Nakamura C, Uji H, Hasegawa H, Eda S (1989) Fate of silicone oil component of a root canal filling material embedded in rat subcutaneous tissue. *Matsumoto Shigaku* **15**, 167–72.
- Kawakami T, Yoshikawa M, Eda S (1990) Tissue reactions to dimethylpolysiloxane embedded subcutaneously in rats. *Medical Science Research* **18**, 485–7.
- Kehoe JC (1987) pH reversal following *in vitro* bleaching of pulpless teeth. *Journal of Endodontics* **13**, 6–9.
- Kennedy GDC, McLundy AC, Day RM (1967) Calcium hydroxide. Its role in a simplified endodontic technique. *Dental Management and Oral Topics* **84**, 51–7.
- Kitagawa M (1969) Clinico-pathological study on immediate root canal filling with improved Calvital after vital pulp extirpation. *Journal of the Tokyo Dental College Society* **69**, 2–5.
- Kleier DJ, Averbach RE, Kawulok TC (1985) Efficient calcium hydroxide placement within the root canal. *Journal of Prosthetic Dentistry* **53**, 509–10.
- Kleier W, Barr ES (1991) A study of endodontically apexified teeth. *Endodontics and Dental Traumatology* **7**, 112–7.
- Klein SH, Levy BA (1974) Histologic evaluation of induced apical closure of a human pulpless tooth. Report of a case. *Oral Surgery, Oral Medicine and Oral Pathology* **38**, 954–9.
- Kokubo K (1981) Studies on the rapidity of root resorption after pulpotomy in primary teeth. *Journal of the Tokyo Dental College Society* **81**, 963–1005.
- Krakow AA, Berck H, Gion P (1974) Tratamiento de la pulpa vital en la dentición permanente. In: *Actas del Segundo Seminario de la Sociedad Argentina de Endodoncia*. Buenos Aires: Argentina.
- Krakow AA, Berck H, Gion P (1977) Therapeutic induction of root formation in the exposed incompletely formed tooth with vital pulp. *Oral Surgery, Oral Medicine and Oral Pathology* **43**, 755–65.
- Kurimoto H (1961) Experimental studies on the conservative treatment of experimental periapical lesion on the trial application of 'Calsan B' as a root canal filling material. *Journal of the Osaka University Dental Society* **6**, 333–52.
- Laurichesse J-M (1980) Le traitement endodontique des dents immatures par éducation apicale (apexification). *Actualités Odontostomatologiques* **131**, 459–76.
- Laws AJ (1962) Calcium hydroxide as a possible root filling material. *New Zealand Dental Journal* **58**, 199–215.
- Laws AJ (1971) Condensed calcium hydroxide root filling following partial pulpotomy. *New Zealand Dental Journal* **67**, 161–8.
- Lawson BF, Mitchell DF (1964) Pharmacologic treatment of painful pulpitis. A preliminary, controlled double-blind study. *Oral Surgery, Oral Medicine and Oral Pathology* **17**, 47–61.

- Lecazadiu M (1986) Pharmacologic endodontique. In: Laurichesse J-M, Maestroni F, Breillat J, eds. *Endodontie Clinique*. Paris: Éditions CDP.
- Leksell E, Ridell K, Cvek M, Mejäre I (1996) Pulp exposure after step-wise versus direct complete excavation of deep carious lesion in young posterior permanent teeth. *Endodontics and Dental Traumatology* **12**, 192–6.
- Lengheden A, Blomlof L, Lindskog S (1991) Effect of immediate calcium hydroxide treatment and permanent root-filling on periodontal healing in contaminated replanted teeth. *Scandinavian Journal of Dental Research* **99**, 139–46.
- Leonardo MR (1973) Contribuição para o estudo da reparação apical e periapical pós-tratamento de canais radiculares (Thesis). Araraquara.
- Leonardo MR, Almeida WA, Ito IY, Silva LAB (1994) Radiographic and microbiologic evaluation of posttreatment apical and periapical repair of root canal of dogs' teeth with experimentally induced chronic lesion. *Oral Surgery, Oral Medicine and Oral Pathology* **78**, 232–8.
- Leonardo MR, Almeida WA, Silva LAB, Utrilla S (1995) Histopathological observations of periapical repair in teeth with radiolucent areas submitted to two different methods of root canal treatment. *Journal of Endodontics* **21**, 137–41.
- Leonardo MR, Araujo CM, Mendes AJD (1976) Contribuição para o emprego de pasta de hidróxido de cálcio na obturação dos canais radiculares. Parte I. *Revista da Faculdade de Farmácia e Odontologia de Araraquara* **10**(suppl. I), 125–35.
- Leonardo MR, Bonetti Filho I, Silva RS, Silva LAB (1993a) Penetrabilidade do “curativo de demora” no sistema de canal radicular. Avaliação de diferentes produtos. *RGO* **41**, 199–203.
- Leonardo MR, Leal JM (1991) *Endodontia Tratamento dos Canais Radiculares*, 2nd edn. São Paulo: Panamericana.
- Leonardo MR, Leal JM, Esberard RM (1978a) Tratamento de canais radiculares de dentes com rizogênese incompleta. Estudo clínico e radiográfico. *ARS CURANDI em Odontologia* **5**, 29–34.
- Leonardo MR, Leal JM, Esberard RM, Lia RCC (1978b) Tratamiento de conductos radiculares de dientes com rizogenesis incompleta. Estudio clínico, radiográfico y histológico. *Revista de la Asociación Odontológica Argentina* **66**, 85–90.
- Leonardo MR, Leal JM, Lia RCC, Martins JCR (1991) Filosofia do tratamento de canais radiculares. Necropulpectomia: conceituação. In: Leonardo MR, Leal JM, eds. *Endodontia Tratamento dos Canais Radiculares*, 2nd edn. São Paulo: Panamericana.
- Leonardo MR, Leal JM, Simões Filho AP (1982) *Endodontia Tratamento dos Canais Radiculares*. São Paulo: Panamericana.
- Leonardo MR, Reis RT, Silva LAB, Loffredo LCM (1992) Hidróxido de cálcio em Endodontia. Avaliação da alteração do pH e da liberação de íons cálcio em produtos endodônticos à base de hidróxido de cálcio. *RGO* **40**, 69–72.
- Leonardo MR, Silva RS, Silva LAB, Assed S (1993c) Determinação de íons Ca^{2+} pH e solubilidade de pastas à base de hidróxido de cálcio contendo paramonoclorofenol e paramonoclorofenol canforado. *Revista Brasileira de Odontologia* **50**, 5–10.
- Leonardo MR, Silva LAB, Utrilla LS, Leonardo RT, Consolaro A (1993b) Effect of intracanal dressings on repair and apical bridging of teeth with incomplete root formation. *Endodontics and Dental Traumatology* **9**, 25–30.
- Lessi RA, Alvares S (1988) Tratamento de dentes permanentes com rizogênese incompleta com ou sem lesão periapical. In: Alvares S, ed. *Endodontia Clínica*. São Paulo: Livraria C Editora Santos.
- Levy S (1980) L'apexification traitement endodontique des dents immatures. *Revue d'Odontostomatologie du Midi de la France* **38**, 93–112.
- Lopes HP (1987) *O emprego do hidróxido de cálcio associado a veículo oleoso no tratamento endodôntico de dentes com mortificação pulpar e ápice aberto* (Thesis). Rio de Janeiro: .
- Lopes HP, Costa Filho AS (1984) Tratamento endodôntico de dentes com rizogênese incompleta e necrose pulpar. *Revista Brasileira de Odontologia* **41**, 2–12.
- Lopes HP, Costa Filho AS, Jones J Jr (1986) O emprego do hidróxido de cálcio associado ao azeite de oliva. *RGO* **34**, 306–13.
- Lopes HP, Estrela C, Siqueira JF Jr (1998) Tratamento endodôntico em dentes com rizogênese incompleta. In: Berger CA, ed. *Endodontia*. São Paulo: Pancast.
- Lopes HP, Estrela C, Siqueira JF Jr, Fava LRG (1996) Considerações químicas, microbiológicas e biológicas do hidróxido de cálcio. *Odontomaster* **1**, 1–17.
- Ludlow MO (1979) Apical closure after nonsurgical apical curetage. *Journal of Endodontics* **5**, 151–3.
- Luvizotto AAV, Valdrighi L, Berbert CV, Murgel CAF (1996) Apeçificação. Formação de barreira apical em dentes imaturos com necrose pulpar. *RGO* **44**, 287–91.
- Machida Y (1960) A clinico-pathological study on pulp extirpation and pulp amputation in middle portion of the root canal. *Japanese Journal of Conservative Dentistry* **3**, 126–89.
- Mackie IC, Bentley EM, Worthington HV (1988) The closure of open apex in non-vital immature incisor teeth. *British Dental Journal* **165**, 169–73.
- Mackie IC, Hill FJ, Worthington HV (1994) Comparison of two calcium hydroxide pastes used for endodontic treatment of non-vital immature incisor teeth. *Endodontics and Dental Traumatology* **10**, 88–90.
- Maeda T (1960) Experimental studies on root canal filling using calcium hydroxidepolyethylene glycol paste with the addition of antibacterial agents. *Journal of the Osaka University Dental Society* **5**, 57–62.
- Maisto OA (1975) *Endodoncia*, 3rd edn. Buenos Aires: Mundi.
- Maisto OA, Capurro MA (1964) Obturación de conductos radiculares con hidróxido, de cálcio-iodoformo. *Revista de la Asociación Odontológica Argentina* **52**, 167–73.

- Malo PRT, Kessler Nieto F, Vadillo MVM (1987) Hidróxido, de calcio y apicoformación *Revista Española de Endodoncia* **5**, 41–61.
- Manfredi EE (1971) Pasta de hidróxido de calcio-iodoformo en obturación de conductos radiculares. *Odontologia Uruguaya* **26**, 17–24.
- Marais JT (1996) The use of calcium hydroxide as a dressing in root canal treatment. *Journal of Dental Association of South Africa* **51**, 593–9.
- Marmasse A (1953) *Dentisterie Operatoire*, vol. 1. Paris: JB Baillière.
- Marques JLL, Conti R, Antoniazzi JH, Gutz I (1994) Avaliação da velocidade de dissociação iônica do hidróxido de calcio associado a diferentes veículos. *Revista de Odontologia Da USP* **8**, 81–7.
- Martin DM, Crabb HSM (1977) Calcium hydroxide in root canal therapy. *British Dental Journal* **142**, 277–83.
- Martins TB, Bernardineli N, Berbert A, Bramante CM, Marques ALV, Lopes S (1979) Efeitos da biomecânica e de curativos de demora com hidróxido de calcio, paramonoclorofenol a 1% ou associação de ambos na redução da flora microbiana de canais radiculares infectados. *ARS CURANDI em Odontologia* **6**, 44–57.
- Massler M, James E, Englander H (1957) Histologic response of amputated pulps to calcium compounds and antibiotics. *Oral Surgery, Oral Medicine and Oral Pathology* **10**, 957–80.
- Masterton JB (1964) The healing of wounds of the dental pulp. *University of Newcastle Medical Gazette* **March**.
- Masterton JB (1966) The healing of wounds of the dental pulp. An investigation of the nature of the scar tissue and of the phenomena leading to its formation. *Dental Practitioner* **16**, 325–39.
- Matsumiya S, Kitamura M (1960) Histopathological and histobacteriological studies of the relation between the condition of sterilization of the interior of the root canal and the healing process of periapical tissues in experimentally infected root canal treatment. *Bulletin of the Tokyo Dental College* **1**, 1–19.
- Matsumoto K, Inoue K, Matsumoto A (1989) The effect of newly developed root canal sealers on rat dental pulp cells in primary culture. *Journal of Endodontics* **15**, 60–7.
- Matsuzaki K, Fujii H, Machida Y (1990) Experimental study of pulpotomy with calcium hydroxide-iodoform paste in dogs' immature permanent teeth. *Bulletin of the Tokyo Dental College* **31**, 9–15.
- Mauricio CV, Lia RCC, Leonardo MR, Benatti Neto C (1987) Estudo histomorfofisiológico do tecido conjuntivo subcutâneo do rato ao implante de pasta à base de hidróxido de calcio contidas em tubos de dentina humana. *Revista de Odontologia Da UNESP* **15/16**, 23–38.
- McMillan DG (1971) Endodontic treatment of permanent teeth with incomplete root end formation. *Northwestern Dentistry* **50**, 398–400.
- Metzler RS, Montgomery S (1989) The effectiveness of ultrasonics and calcium hydroxide for the debridement of human mandibular molars. *Journal of Endodontics* **15**, 373–8.
- Michanowicz J, Michanowicz A (1967) A conservative approach and procedure to fill incompletely formed root using calcium hydroxide as an adjunct. *Journal of Dentistry for Children* **32**, 42–7.
- Milosevic A (1991) Calcium hydroxide in restorative dentistry. *Journal of Dentistry* **19**, 313.
- Mitchell DF, Shankwalker GB (1958) Osteogenic potential of calcium hydroxide and other materials in soft tissue and bone wounds. *Journal of Dental Research* **37**, 1157–63.
- Montgomery S (1984) External cervical resorption after bleaching a pulpless tooth. *Oral Surgery, Oral Medicine and Oral Pathology* **57**, 203–6.
- Moraes SH, Aragão EM, Heck AR, Kosinski CD (1992) Influência das técnicas de irrigação em Endodontia. *Revista Odontológica do Brasil Central* **2**, 30–2.
- Morgan RW, Carnes DC Jr, Montgomery S (1991) The solvent effects of calcium hydroxide irrigating solution on bovine pulp tissue. *Journal of Endodontics* **17**, 165–8.
- Morse DR, O'Larnic J, Yesilsoy C (1990) Apexification: review of the literature. *Quintessence International* **21**, 589–98.
- Motta AG, Apfel MIR, Motta AG Jr (1997) Reação do tecido conjuntivo, subcutâneo de implantes contendo Apexit, Calen e L & C. *Revista Brasileira de Odontologia* **54**, 29–33.
- Murata S (1959) Experimental study on treatment of infected root canal of deciduous tooth with application of calcium hydroxide-eugenol. *Japanese Journal of Conservative Dentistry* **3**, 163–5.
- Nagakubo T (1969) Clinico-pathological study of the effects of pulp capping with various calcium hydroxide pastes. *Journal of the Tokyo Dental College Society* **691**, 382–439.
- Naulin-Iff C (1986) Apexogenese apexification: données récentes. *Revue Française d'Endodontie* **5**, 75–83.
- Nerwich A, Fidgor D, Messer HH (1993) pH changes in root dentine over a 4-week period following root canal dressing with calcium hydroxide. *Journal of Endodontics* **19**, 302–6.
- Nevens A, Finkelstein F, Laporta R, Borden B (1978) Induction of hard tissues into pulpless open-apex teeth using collagen-calcium phosphate gel. *Journal of Endodontics* **4**, 76–81.
- Nosrat IV, Nosrat CA (1998) Reparative hard tissue formation following calcium hydroxide application after partial pulpotomy in cariously exposed pulps of permanent teeth. *International Endodontic Journal* **31**, 221–6.
- Nyborg H (1955) Healing process in the pulp on capping. A morphologic study. *Acta Odontologica Scandinavica* **13** (Suppl. 16), 1–129.
- Nyborg H, Tullin B (1965) Healing process after vital extirpation. An experimental study of 17 teeth. *Odontologisk Tidskrift* **73**, 430–46.
- Nygren J (1838) *Radgivare Angående Basta Sattet Att Varda Ah Bevara Tandernas Fuskhet*, Osv. Stockholm.
- O'Riordan M (1980) Apexification of deciduous incisor. *Journal of Endodontics* **6**, 607–9.

- Ogawa AT, Holland R, Souza V (1974) Influência do selamento cavitário no processo de reparo, da polpa dental após pulpotomia e proteção com hidróxido de cálcio. *Revista da Faculdade de Odontologia de Araçatuba* **3**, 51–9.
- Ohara PK, Torabinejad M (1992) Apical closure of an immature root subsequent to apical curettage. *Endodontics and Dental Traumatology* **8**, 134–7.
- Okamoto T, Sonoda CK, Velasco-Bohórnez M, Martins AP (1996) Anquilose e reabsorção nos reimplantes dentários. Interferência do ligamento periodontal cementário e alveolar nestas ocorrências. *RGO* **44**, 257–61.
- Oleto EMO, Melo GR (1985) Do emprego do hipoclorito de sódio, paramonoclorofenol e hidróxido de cálcio na necrose pulpar. (Estudo clínico em dentes humanos). *Arquivo do Centro de Estudos do Curso de Odontologia da Universidade Federal de Minas Gerais* **21/22**, 113–26.
- Olson A, Hoover JE (1975) *Remington's Pharmaceutical Sciences*, 15th edn. Easton: Mack Publishing Co.
- Orstavik D, Kerekes K, Molven O (1991) Effects of extensive apical reaming and calcium hydroxide dressing on bacterial infection during apical periodontitis: a pilot study. *International Endodontic Journal* **24**, 1–7.
- Parashos P (1997) Apexification: case report. *Australian Dental Journal* **42**, 43–6.
- Patterson SS, Van Huysen G (1954) The treatment of pulp exposure. *Oral Surgery, Oral Medicine and Oral Pathology* **7**, 194–206.
- Peniche CEC, Sampaio JMP, Collesi RR (1996) Verificação do pH de diversas soluções à base de hidróxido de cálcio. *Revista Odontológica da Universidade de Santo Amaro* **1**, 58.
- Piekoff MD, Trott JR (1976) Apexification: report of a case. *Journal of Endodontics* **2**, 182–5.
- Pinto ACG, Lessi RA (1984) Tratamento endodôntico de dentes com rizogênese incompleta. In: Paiva JG, Antoniazzi JH, eds. *Endodontia. Bases para a Prática Clínica*. São Paulo: Artes Médicas.
- Pissiotis E, Spangberg LSW (1990) Biological evaluation of collagen gels containing calcium hydroxide and hydroxyapatite. *Journal of Endodontics* **16**, 468–73.
- Porkaew P, Retief DH, Barfield RD, Lacefield WR, Soong S (1990) Effects of calcium hydroxide paste as an intracanal medicament on apical seal. *Journal of Endodontics* **16**, 468–73.
- Prokopowitsch I (1994) *Influência do hidróxido de cálcio como medicação intracanal na permeabilidade e limpeza dentinária radicular em dentes portadores de rizogênese incompleta (estudo 'in vitro')* (Thesis). São Paulo.
- Quillin B, Dabirsiaghi CL, Krywolap GN, Dumsha TC (1992) Antimicrobial effect of Ca(OH)₂ supplemented with metronidazole and chlorhexidine as intracanal medicaments (poster clinic no. 15). *Journal of Endodontics* **18**, 187.
- Rabie G, Trope M, Trostad L (1988) Treatment of a maxillary canine with external inflammatory root resorption. *Journal of Endodontics* **14**, 101–5.
- Ramos CAS, Bramante CM (1997) *Endodontia*. Londrina: Editora da UEL.
- Rantanen AV, Louhivuori A (1959) The effect of calcium hydroxide upon human serum proteins. *Acta Odontologica Scandinavica* **17**, 103–11.
- Rehman K, Saunders WP, Foye RH, Sharkey SW (1996) Calcium ion diffusion from calcium hydroxide containing materials in endodontically-treated teeth: an 'in vitro' study. *International Endodontic Journal* **29**, 271–9.
- Reit C, Dahlen G (1988) Decision making analysis of endodontic treatment strategies in teeth with apical periodontitis. *International Endodontic Journal* **21**, 291–9.
- Rezende JA (1982) Tratamento dos dentes permanentes com rizogênese incompleta e polpa necrosada. Oito anos de observação clínico-radiográfica. *Revista da Associação Paulista de Cirurgiões Dentistas* **36**, 436–41.
- Ricci C, Travert V (1987) L'hydroxyde de calcium en endodontie. *Revue Française d'Endodontie* **6**, 45–74.
- Rivera EM, Williams K (1994) Placement of calcium hydroxide in simulated canals: comparison of glycerin versus water. *Journal of Endodontics* **20**, 445–8.
- Rocca JP (1993) Nouveautés endodontiques. Calcigel, Endocal et Hydroxine. *Endodontie* **12**, 17.
- Rohner W (1940) Calxyl als wurzelfüllungs material nach pulpa extirpation. *Schweizer Monatsschrift für Zahnmedizin* **50**, 903–48.
- Rotstein I, Friedman S, Katz J (1990) Apical closure of mature molar roots with the use of calcium hydroxide. *Oral Surgery, Oral Medicine and Oral Pathology* **70**, 656–60.
- Russo MC, Holland R (1974a) Microscopical findings after protection with various dressings in pulpotomized deciduous teeth of dogs. *Revista da Faculdade de Odontologia de Araçatuba* **3**, 113–23.
- Russo MC, Souza V, Holland R (1974b) Effects of the dressing with calcium hydroxide under pressure on the pulpal healing of pulpotomized human teeth. *Revista da Faculdade de Odontologia de Araçatuba* **3**, 303–11.
- Saad AY (1988) Calcium hydroxide and apexogenesis. *Oral Surgery, Oral Medicine and Oral Pathology* **66**, 499–501.
- Safavi KE, Dowden WE, Introcaso JH, Langeland K (1985) A comparison of antimicrobial effects of calcium hydroxide and iodine-potassium iodide. *Journal of Endodontics* **11**, 454–6.
- Sahli CC (1988) L'hydroxyde de calcium dans le traitement endodontique des grandes lésions périapicales. *Revue Française d'Endodontie* **7**, 45–51.
- Sahli CC (1989) Observación radiográfica y estudio histológico de un caso de apicoformación en un molar humano. *Revista Española de Endodoncia* **7**, 101–6.
- Saijio Y (1957) Clinico-pathological study on vital amputation with calcium hydroxide added to various kinds of antibacterial substances. *Journal of the Tokyo Dental College Society* **57**, 357–63.

- Salamat K, Rezai RF (1986) Nonsurgical treatment of extraoral lesions caused by necrotic nonvital teeth. *Oral Surgery, Oral Medicine and Oral Pathology* **61**, 618–23.
- Santini AH (1985) Intraoral comparison of calcium hydroxide (Calnex) alone and in combination with Ledermix in first permanent mandibular molars using two direct inspection criteria. *Journal of Dentistry* **13**, 52–9.
- Santini AH (1986) Long term clinical assessment of pulpotomy with calcium hydroxide containing Ledermix in human permanent premolars and molars. *Acta Odontologica Pediatrca* **7**, 45–50.
- Santos KS (1996) Hidróxido de calcio no tratamento das reabsorções cervicais externas pósclareamento em dente despolpado. *Revista do Conselho Regional de Odontologia de Minas Gerais* **2**, 41–7.
- Sardi MPS, Froener R, Fachin EUF (1995) Hidróxido de calcio como medicação intracanal em casos de necrose pulpar com lesão periapical. *Revista da Faculdade de Odontologia de Porto Alegre* **36**, 17–20.
- Sazak H, Gunday M, Alatti C (1996) Effect of calcium hydroxide and combinations of Ledermix and calcium hydroxide on inflamed pulps in dog teeth. *Journal of Endodontics* **22**, 447–9.
- Schilder H, Amsterdam M (1959) Inflammatory potential of root canal medicaments. *Oral Surgery, Oral Medicine and Oral Pathology* **12**, 211–21.
- Schroeder A (1981) *Endodontics Science and Practice*. Chicago: Quintessence.
- Sekine N, Asai Y, Nakamura Y, Tagami T, Nagakubo T (1971) Clinico-pathological study of the effect of pulp capping with various calcium hydroxide pastes. *Bulletin of the Tokyo Dental College* **4**, 149–73.
- Sekine N, Machida V, Imanishi T (1963a) A clinico-pathological study on pulp extirpation and pulp amputation in the middle portion of the root canal. *Bulletin of the Tokyo Dental College* **4**, 103–35.
- Sekine N, Saijio Y, Ishikawa T, Imanishi T, Asai Y, Narita M (1963b) Clinico-pathological study on vital pulpotomy with Calvital. *Journal of the Tokyo Dental College Society* **63**, 463–73.
- Senzamici NP, Tesini DA (1977) An approach to obturation using apical maturity as a consideration in endodontic treatment of young permanent teeth. *Journal of Pedodontics* **1**, 177–83.
- Shankle RJ, Brauer JS (1962) Pulp capping. *Oral Surgery, Oral Medicine and Oral Pathology* **15**, 1121–7.
- Shay DE, Sarubin LD, Spurrier HS, Sanders DJ (1960) Pulp conservation with an antibiotic agent. *Journal of Dentistry for Children* **36**, 5–12.
- Sheehy EC, Roberts CJ (1997) Use of calcium hydroxide for apical barrier formation and healing in non-vital immature permanent teeth: a review. *British Dental Journal* **183**, 241–6.
- Shibuya T (1980) A histopathological study in dogs on the improvement of a paste for root canal filling. *Journal of the Tokyo Dental College Society* **80**, 417–46.
- Silva LAB (1988) *Rizogênese incompleta. Efeitos de diferentes pastas de hidróxido de calcio na complementação radicular e na reparação periapical de dentes de cães. Estudo histológico* (Thesis). Araraquara.
- Silva LAB, Leonardo MR, Utrilla LS (1991) Rizogênese incompleta. Efeito de diferentes pastas à base de hidróxido de calcio na complementação radicular e na reparação periapical em dentes de cães. Estudo histológico. *Revista de Odontologia Da USP* **5**, 29–36.
- Silva FT, Pugliesi NS, Araujo VC (1996) Resposta do tecido conjuntivo pulpar frente ao hidróxido de calcio PA associado à água destilada e ao hidróxido de calcio associado ao soro fisiológico. *Revista de Pós-Graduação da FOU SP* **3**, 59–65.
- Simon ST, Bhat KS, Francis R (1995) Effect of four vehicles on the pH of calcium hydroxide and the release of calcium ion. *Oral Surgery, Oral Medicine and Oral Pathology* **80**, 459–64.
- Simpson ST (1970) Treatment of the open apex. Pulp involvement through trauma. *Australian Dental Journal* **15**, 392–5.
- Siqueira JF Jr (1996) *Avaliação da invasão bacteriana de túbulos dentinários e da atividade antibacteriana de medicamentos intracanaís* (Thesis). Rio de Janeiro.
- Siqueira JF Jr (1997) *Tratamento das Infecções Endodônticas*. Rio de Janeiro: MEDSI.
- Siqueira JF Jr, Fraga RC (1995) Influência da medicação intra-canal com pastas à base de Ca(OH)₂ no selamento apical – efeito do veículo. *Revista Brasileira de Odontologia* **52**, 46–8.
- Siqueira JF Jr, Lopes HP, Magalhães FAC, Uzeda M (1997) Atividade antibacteriana da pasta de hidróxido de calcio/paramonoclorofenol canforado/glicerina contendo diferentes proporções de iodofórmio sobre bactérias anaeróbias estritas e facultativas. *Revista Paulista de Odontologia* **19**, 17–21.
- Siqueira JF Jr, Magalhães FAC, Uzeda M (1996) Avaliação da atividade antibacteriana da medicação intracanal. *RGO* **44**, 271–4.
- Siqueira JF Jr, Uzeda M (1996) Disinfection by calcium hydroxide pastes of dentinal tubules infected with two obligate and one facultative anaerobic bacteria. *Journal of Endodontics* **22**, 674–6.
- Siqueira JF Jr, Uzeda M (1997) Intracanal medicaments: evaluation of the antibacterial effects of chlorhexidine, metronidazole and calcium hydroxide associated with three vehicles. *Journal of Endodontics* **23**, 167–9.
- Sjogren U, Fidgor D, Spangberg L, Sundqvist G (1991) The antimicrobial effects of calcium hydroxide as a short-term intracanal dressing. *International Endodontic Journal* **24**, 119–25.
- Smith JW, Leeb JJ, Torney DL (1984) A comparison of calcium hydroxide and barium hydroxide as agents for inducing apical closure. *Journal of Endodontics* **10**, 64–70.
- Smith GN, Woods S (1983) Organic iodine: a substitute for BaSO₄ in apexification procedures. *Journal of Endodontics* **9**, 153–5.

- Soares I, Felipe MC, Lucena M (1996) Tratamento de dentes com rizogênese incompleta. *Revista da ABO Nacional* **4**, 26–31.
- Sommer RF, Ostrander FD, Crowley MC (1975) *Endodontia Clínica*. Barcelona: Labor.
- Souza V, Holland R, Mello W, Nery MJ (1977) Reaction of rat connective tissue to the implant of calcium hydroxide pastes. *Revista da Faculdade de Odontologia de Araçatuba* **6**, 39–46.
- Souza V, Bernabé PFE, Holland R, Nery MJ, Mello W, Otoboni Filho FA (1989) Tratamento não cirúrgico de dentes com lesões periapicais. *Revista Brasileira de Odontologia* **46**, 39–46.
- Souza Neto MD, Vansan LP, Silva RG, Pécora JD (1991) Reabsorção interna: relato de dois casos clínicos submetidos a diferentes técnicas de obturação dos canais radiculares. *Revista Paulista de Odontologia* **13**, 10–4.
- Spangberg LSW (1994) Intracanal medication. In: Ingle JI, Bakland LK, eds. *Endodontics*, 4th edn. Baltimore: Williams & Wilkins.
- Stamos DG, Haash G, Gerstein H (1988) The pH of local anesthetic/calcium hydroxide solution. *Journal of Endodontics* **11**, 264–5.
- Steiner JC, Dow PR, Cathey GM (1968) Inducing root end closure of non-vital teeth. *Journal of Dentistry for Children* **55**, 47–54.
- Steiner JC, Van Hassel HJ (1971) Experimental root apexification in primates. *Oral Surgery, Oral Medicine and Oral Pathology* **31**, 409–15.
- Stevens RH, Grossman LI (1983) Evaluation of the antimicrobial potential of calcium hydroxide as an intracanal medicament. *Journal of Endodontics* **9**, 372–4.
- Stewart GG (1975) Calcium hydroxide-induced root healing. *Journal of the American Dental Association* **90**, 793–800.
- Stock CJR (1985) Calcium hydroxide: root resorption and perio-endo lesions. *British Dental Journal* **158**, 325–34.
- Stromberg T (1969) Wound healing after total pulpectomy in dogs. A comparative study between root fillings with calcium hydroxide, dibasic calcium phosphate and gutta-percha. *Odontologisk Revy* **20**, 147–63.
- Stuart KG, Moller CH, Brown CE Jr, Newton CW (1991) The comparative antimicrobial effect of calcium hydroxide. *Oral Surgery, Oral Medicine and Oral Pathology* **72**, 101–4.
- Sundqvist G, Fidgor D, Persson S, Sjogren U (1998) Microbiologic analysis of teeth with failed endodontic treatment and the outcome of conservative re-treatment. *Oral Surgery, Oral Medicine and Oral Pathology* **85**, 86–93.
- Sydney GB (1996) *Identificação da microflora endodôntica após o preparo do canal radicular de dentes portadores de periodontite apical assintomática e o emprego de medicação de hidróxido de cálcio em diferentes tempos* (Thesis). São Paulo.
- Taguchi M (1972) A clinico-pathological study of pulpotomy in the middle portion of the root canal of vital human deciduous teeth. *Journal of the Tokyo Dental College Society* **72**, 647–94.
- Taintor JF (1977) Technic for root end closure: apexification. *Journal of the Nebraska Dental Association* **53**, 26.
- Takeuti ML, Marques JLL, Antoniazzi JH (1997) Penetração dentinária da associação hidróxido de cálcio, ciprofloxacina e metronidazol variando o veículo. *Revista de Pós-Graduação da FOUASP* **4**, 146–52.
- Tamburic SD, Vuleta GM, Ognjanovic JM (1993) In vitro release of calcium and hydroxyl ions from two types of calcium hydroxide preparations. *International Endodontic Journal* **26**, 125–30.
- Tavano O, Damante JH, Estevam E, Alvares LC (1978) Sialografia das glândulas parótidas e submandibulares. In: *Prática Odontológica*, vol. 1. Rio de Janeiro: Richardson Merrell-Moura.
- Tenca JJ, Tsamtouris A (1978) Continued root end development apexogenesis and apexification. *Journal of Pedodontics* **2**, 144–57.
- Teplitsky P (1986) McSpadden compactor. Vertical condensation technique to deliver calcium hydroxide. *Journal of the Canadian Dental Association* **52**, 779–81.
- Teuscher GW, Zander HA (1938) A preliminary report on pulpotomy. *Northwestern University Bulletin* **39**, 4.
- Thater M, Marechaux SC (1988) Induced root apexification following traumatic injury of the pulp in children: follow-up study. *Journal of Dentistry for Children* **55**, 109–15.
- Torneck CD, Moe H, Howley TP (1983) The effect of calcium hydroxide on porcine fibroblasts in vitro. *Journal of Endodontics* **9**, 131–6.
- Torneck CD, Smith JS, Grindall B (1973) Biologic effects of endodontic procedures on developing incisor teeth. IV – Effect of debridement procedures and calcium hydroxide-camphorated parachlorophenol paste in the treatment of experimentally induced pulp and periapical disease. *Oral Surgery, Oral Medicine and Oral Pathology* **35**, 541–54.
- Tronstad L, Mjor IA (1972) Pulp reactions to calcium hydroxide-containing materials. *Oral Surgery, Oral Medicine, Oral Pathology* **33**, 961–5.
- Tronstad L, Andreasen JO, Hasselgren G, Kristerson L, Riis I (1981) pH changes in dental tissues after root canal filling with calcium hydroxide. *Journal of Endodontics* **7**, 17–21.
- Trope M, Moshonov J, Nissan R, Buxt P, Yesilsoy C (1995) Short vs. long-term calcium hydroxide treatment of established inflammatory root resorption in replanted dog teeth. *Endodontics and Dental Traumatology* **11**, 124–8.
- Trope M, Yesilsoy C, Koren L, Moshonov J, Friedman S (1992) Effect of different endodontic treatment protocols on periodontal repair and root resorption of replanted dog teeth. *Journal of Endodontics* **18**, 492–6.
- Tsuchima T (1970) Clinico-pathological study of immediate root canal filling with paste, gutta-percha point and combination of the two after vital pulp extirpation. *Journal of the Tokyo Dental College Society* **70**, 1–4.
- Tuero E (1974) Conservación de la integridad pulpar y extirpación parcial de la pulpa. *Actas del Segundo Seminario de la Sociedad Argentina de Endodoncia*. Argentina: Buenos Aires.
- Tziafas D, Molyvdas I (1988) The tissue reactions after pulp capping of dog teeth with calcium hydroxide experimentally

- crammed into the pulp space. *Oral Surgery, Oral Medicine and Oral Pathology* **65**, 604–8.
- Ulyseia PM, Oldra R, Silveira LFM (1992) Avaliação de diferentes métodos de aplicação do hidróxido de cálcio no canal radicular. *Revista da Faculdade de Odontologia de Pelotas* **213**, 38–41.
- United States Pharmacopeia (1989) 22nd revision. Rockville: The United States Pharmacopeial Convention, Inc.
- Van Hassel HJ, Natkin E (1969) Induction of foraminal closure. *Journal of the Canadian Dental Association* **35**, 606–8.
- Van Hassel HJ, Natkin E (1970) Induction of root end closure. *Journal of Dentistry for Children* **37**, 57–9.
- Vander Wall GL, Dowson J, Shipman C (1972) Antibacterial efficacy and cytotoxicity of three endodontic drugs. *Oral Surgery, Oral Medicine and Oral Pathology* **33**, 230–41.
- Varella JAF, Paiva JG, Villa N (1966) O uso de corticosteróides no tratamento conservador da polpa. *Revista da Faculdade de Odontologia Da USP* **4**, 153–64.
- Vernieks AA (1978) Calcium hydroxide induced healing of periapical lesions: a study of 78 non-vital teeth. *Journal of the British Endodontic Society* **11**, 61–9.
- Vojinovic O, Srnie E (1975) Induction of apical formation by the use of calcium hydroxide and iodoform-Chlumsky paste in endodontic treatment of immature teeth. *Journal of the British Endodontic Society* **8**, 16–22.
- Wakabayashi H, Horikawa M, Funaro A, Onodera A, Matsumoto K (1993) Biomicroscopical observation of dystrophic calcification induced by calcium hydroxide. *Endodontics and Dental Traumatology* **9**, 165–70.
- Wakabayashi H, Morita S, Koba K, Tachibana H, Matsumoto K (1995) Effect of calcium hydroxide paste dressing on uninstrumented root canal wall. *Journal of Endodontics* **21**, 543–5.
- Wakai WT, Naito RM (1974) Endodontic management of teeth with incompletely formed roots. *Journal of the Hawaii Dental Association* **7**, 13–9.
- Walton RE, Torabinejad M (1989) Cleaning and shaping. In: Pedersen P, ed. *Principles and Practice of Endodontics*. Philadelphia: Saunders.
- Watanabe I (1969) Clinico-pathological study on vital pulp amputation in patients of advanced age. *Journal of the Tokyo Dental College Society* **69**, 1–43.
- Webber RT (1983) Traumatic injuries and the expanded endodontic role of calcium hydroxide. In: Gerstein H, ed. *Techniques in Clinical Endodontics*. Philadelphia: Saunders.
- Webber RT (1984) Apexogenesis versus apexification. *Dental Clinics of North America* **28**, 669–97.
- Webber RT, Schwiebert KA, Cathey GM (1981) A technique for placement of calcium hydroxide in the root canal system. *Journal of the American Dental Association* **103**, 417–21.
- Wechsler SM, Fishelberg G, Opderbeck WR (1978) Apexification: a valuable and effective clinical procedure. *General Dentistry* **26**, 40–3.
- Weinstein R, Goldman M (1977) Apical hard-tissue deposition in adult teeth of monkeys with use of calcium hydroxide. *Oral Surgery, Oral Medicine and Oral Pathology* **43**, 627–30.
- Weiss M (1966) Pulp capping in older patients. *New York State Dental Journal* **32**, 451–7.
- West NM, Lieb RJ (1985) Biologic root-end closure on a traumatized and surgically resected maxillary central incisor: an alternative method of treatment. *Endodontics and Dental Traumatology* **1**, 146–9.
- Winter GB (1977) Endodontic therapy of traumatized teeth in children. *International Endodontic Journal* **27**, 252–62.
- Yacometti P (1952) Experiência de capeamento da polpa. *Rio Grande Odontológico* **11**, 5–7.
- Yang S-F, Rivera EM, Baungardner KR, Walton RE, Stanford C (1995) Anaerobic tissue dissolving abilities of calcium hydroxide and sodium hypochlorite. *Journal of Endodontics* **21**, 613–6.
- Yang S-F, Yang Z-P, Chang K-W (1990) Continuing root formation following apexification treatment. *Endodontics and Dental Traumatology* **6**, 232–5.
- Yates JA (1988) Barrier formation time in non-vital teeth with open apices. *International Endodontic Journal* **21**, 313–9.
- Yoshida K, Yoshida N, Iwaku M (1994) Histological observations of hard tissue barrier formation in amputated dental pulp capped with a-tricalciumphosphate containing calcium hydroxide. *Endodontics and Dental Traumatology* **10**, 113–20.
- Zander HA (1939) Reaction of the dental pulp to calcium hydroxide. *Journal of Dental Research* **181**, 373–9.
- Zelante A, Oliveira MRB, Lia RCC, Benatti Neto C (1992) Compatibilidade biológica em tecido conectivo subcutâneo do rato, de pastas à base de hidróxido de cálcio contidas em tubos de dentina humana. *Revista de Odontologia da UNESP* **21**, 37–46.