

Consideration of steroids for endodontic pain

J. GORDON MARSHALL

Up to 80% of endodontic patients who report with preoperative pain continue to experience some level of pain following the endodontic procedure. Since endodontic pain is often associated with chronic inflammation, the presence of bacterial by-products, influx of primed immune cells and activation of the cytokine network and other inflammatory mediators, pain may be reduced by administration of glucocorticoid steroids. This review will include the pharmacology, pharmacodynamics and purported mechanisms of actions of steroids as well as their indications for endodontics, contraindications, dosages and side-effects.

Endodontic post-treatment pain continues to be a significant problem facing the dental profession (1, 2). For those patients presenting with preoperative pain, it has been reported that up to 80% of this population will continue to report pain after endodontic treatment, with pain levels ranging from mild to severe (3–5). Many studies (3–13) have demonstrated that endodontic treatment either in the form of pulpotomy or pulpectomy is efficacious in reducing post-treatment pain (for details, see article by P. Rosenberg in this issue of *Endodontic Topics*). As can be seen (Fig. 1) the pain relief afforded by endodontic treatment is effective but rarely immediate and complete. Post-treatment pain is usually mild in nature rarely lasts longer than 72 h and is usually well managed with non-steroidal anti-inflammatory agents (NSAID) or acetaminophen.

However, some patients will continue to have pain at moderate to severe levels that persists for several days even after appropriate endodontic treatment. For example, in patients who present for treatment with a diagnosis of a symptomatic necrotic tooth, 47–60% may expect moderate to severe pain in the first 24 h post treatment and 16–24% of patients at 72 h postoperatively (14, 15). From these studies, it is evident that post-treatment analgesic intervention is required in a variable percentage of endodontic cases.

Numerous clinical studies have evaluated the effi-

cacy of a wide variety of analgesics for their ability to ameliorate dental pain (8, 9, 11, 16–18). Most of these studies have used an oral surgical third molar extraction model that evaluated pain of an acute inflammatory nature. In contrast, endodontic pain is often associated with chronic inflammation, the presence of bacterial by-products, influx of primed immune cells and activation of the cytokine network and

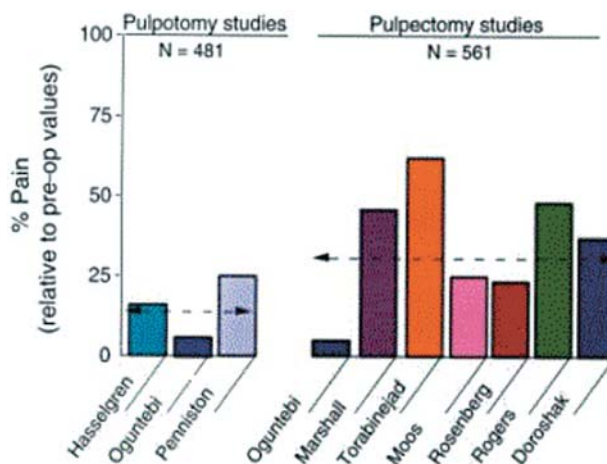


Fig. 1. Effect of pulpotomy on pulpectomy procedures on reducing post-treatment endodontic pain (100% = pre-operative level of pain). From: Hargreaves KM & Baumgartner JC. *Endodontic Therapeutics*. In: Walton R, Torabinejad M, eds. *Principles and practice of endodontics*. Philadelphia: WB Saunders, pp 530–544, 2002 (20).

other inflammatory mediators (19). The chronicity of pulpal and periapical inflammation may permit sprouting of nociceptor terminals and thus change the peripheral anatomy of the pain system (21). It is possible that the efficacy of analgesics differs when comparing the pain associated with acute postoperative inflammation due to oral surgery, with pain associated with the more persistent inflammatory process observed in endodontic pain patients.

Various classes of drugs have been studied for the management of post-treatment endodontic pain (3, 4, 9, 11, 13, 14). These include non-narcotic analgesics comprising NSAID's and acetaminophen, opioids and steroids. The purpose of this article is to consider the use of steroids specifically glucocorticoids in the management of endodontic pain. This review will focus on the pharmacology, purported mechanisms of actions of steroids, as well as their indications for endodontics, contraindications, dosages and side-effects. The history of steroid use in endodontics will be covered as well as a critical evaluation of the research done to date on the effects of glucocorticoids on endodontic post-treatment pain.

The adrenal cortex synthesizes fat-soluble corticosteroids from cholesterol. These steroids contain 21 carbon atoms in a four membered hydrocarbon ring system. Corticosteroids comprise glucocorticoids and mineral corticoids. This review focuses on the glucocorticoids since they act at multiple sites to inhibit immune and inflammatory reactions. In humans, cortisol is the primary glucocorticoid that is continuously synthesized and secreted from the adrenal cortex. This process is under the control of the hypothalamus and anterior pituitary. Along with the adrenal cortex, they make up the hypothalamic-pituitary-adrenal (HPA) axis, a system that regulates glucocorticoid levels (22). The hypothalamus produces corticotropin-releasing hormone (CRH), which travels to the anterior pituitary via the hypothalamic-hypophyseal portal system and stimulates the release of adrenocorticotrophic hormone (ACTH) by pituitary corticotropes. ACTH, a peptide of 39 amino acids, is the main regulator of cortisol secretion. In turn, glucocorticoids inhibit ACTH secretion via direct and indirect actions inhibiting (CRH) neurons resulting in decreased CRH release, and via direct effects on corticotropes.

Cortisol and synthetic glucocorticoids circulate in the blood with 90% or more reversibly bound to plasma proteins. Two circulating plasma proteins,

albumin and corticosteroid-binding globulin (CBG or transcortin), account for most of these steroid binding sites. Only the unbound portion of corticosteroid is free to enter cells and mediate effects; thus, 90% of total plasma concentration of steroids is not pharmacologically active. Cortisol has a biologic half-life of approximately 90 min.

Chemical modifications of the cortisol molecule have produced a number of synthetic glucocorticoids with greater biologic half-lives, greater anti-inflammatory properties and less mineral corticoid activity (Table 1). The adrenal cortex produces approximately 10 mg/day of cortisol in the non-stressed adult (22). Under severe stress, this level may be increased more than 10 fold. The metabolism of steroids takes place in hepatic and extrahepatic sites and involves sequential additions of oxygen or hydrogen molecules followed by conjugation to form water-soluble derivatives that are excreted in urine. Little biliary or fecal excretion of steroids is seen in human beings.

Glucocorticoids inhibit the production by multiple cells or factors that are important in producing the inflammatory response. This inhibition is a result of the effect of glucocorticoids on gene transcription that produces a decrease in the release of vasoactive and chemoattractive factors, decreased secretion of lipolytic and proteolytic enzymes, decreased extravasation of leukocytes to areas of tissue injury, and ultimately decreased fibrosis (22). Glucocorticoids also produce profound effects on the immune response by inhibition of cytokine production, specifically interferon γ , granulocyte/monocyte colony stimulating factor (GM-CSF), interleukins 1, 2, 3, 6 (IL-1, IL-2, IL-3, IL-6) and tumor necrosis factor α (TNF α) (Table 2). Thus, the pharmacological effects of glucocorticoids oppose many of the inflammatory processes that are known to occur during periapical inflammation. Indeed, the ability of glucocorticoids to decrease periapical inflammation after endodontic treatment has been demonstrated in a dog model by both Holland (23), and Smith et al. (24). Glucocorticoids bind non-covalently with specific receptor proteins in target tissues to regulate the expression of corticosteroid-responsive genes. These receptors have high specificity and affinity for natural or synthetic glucocorticoids. Once formed, the cytoplasmic hormone-receptor complex becomes activated and enters the cell nucleus where it directs the transcription of specific mRNA. The newly formed mRNA is

processed within the nucleus and then translocates to the ribosomes to serve as a template for newly synthesized proteins that are responsible for the biologic effects (25). Examples of steroid-induced protein synthesis include lipocortin 1, a 37-kDa protein that has antiphospholipase A₂ activity (26). Lipocortins prevent the synthesis of arachadonic acid and thereby reduce the biosynthesis of both cyclo-oxygenase and lipoxygenase products, including prostaglandins, leukotrienes and thromboxane related substances (25). From this perspective, lipocortins represent one of the body's natural 'NSAID-like' proteins. Glucocorticoids also inhibit the induction of the gene coding for COX-2 in monocytes (26).

Reductions in pulpal levels of both PGE₂ and IL-8 in cases of untreated irreversible pulpitis have been demonstrated after the administration of the glucocorticoid Depo-Medrol (27). Forty patients with a diagnosis of irreversible pulpitis randomly received, in a double blind fashion, an intraosseous injection (IO) of either 40 mg of methylprednisolone or sterile saline. No endodontic treatment was performed, the teeth were extracted at either 1 or 3 days after IO injection and pulp tissue was removed. Enzyme immunoassay of the pulp tissue demonstrated a significantly lower concentration of PGE₂ at 1 day post steroid injection. Mean pulpal concentrations of IL-8 in the steroid group were only 17% that of levels ob-

served in the saline group at 1 day, but this difference was not statistically significant. Thus, steroid treatment to endodontic patients results in significant reductions in pulpal concentrations of PGE₂, with a trend towards a reduction in cytokine levels.

Glucocorticoids also induce synthesis of kinase II or angiotensin converting enzyme (ACE), which can lead to a reduction of bradykinin. Bradykinin has four main pro-inflammatory actions including vasodilation, increased vascular permeability, leukocyte chemoattraction, and nociceptor activation (28). Bradykinin activates sensory nociceptors and elicits release of substance P, neurokinin A, and calcitonin gene-related peptide (CGRP) via receptors B₁ and B₂. The pain of acute inflammation appears to be mediated by B₂ receptors, whereas the pain of chronic inflammation appears to involve an increased number of B₁ receptors (29). Reduction of bradykinin levels and postoperative pain by the administration of glucocorticoids has been demonstrated by Hargreaves & Costello (30) using microdialysis probes in the oral surgery model.

Glucocorticoids have also been shown to produce a protein termed 'vasocortin', which has the ability to suppress edema that is not suppressed by NSAIDs (22). Nitric oxide synthase is inducible by pro-inflammatory cytokines resulting in increased nitric oxide production. Nitric oxide may increase blood flow and

Table 1. Pharmacokinetics and relative potencies of corticosteroids

Corticosteroid	Plasma t _{1/2} (minutes)	Tissue t _{1/2} (hours)	Anti-inflammatory potency	Na ⁺ -retaining potency	Equivalent dose (mg)*
Cortisol	90	8-12	1	1	20
Cortisone	30	8-12	0.8	0.8	25
Prednisone	60	12-36	4	0.8	25
Prednisolone	200	12-36	4	0.8	5
6 α -Methylprednisolone	180	12-36	5	0.5	4
Fludrocortisone	200	8-12	10	125	**
Triamcinolone	300	12-36	5	0	4
Betamethasone	100-300	36-54	25	0	0.75
Dexamethasone	100-300	36-54	25	0	0.75

* Dosages are approximate and apply to oral or intravenous administration, as glucocorticoid potencies may vary greatly following intramuscular administration.

** This agent is not used for glucocorticoid effects.

Table 2. Effects of glucocorticoids on components of inflammatory/immune responses (adapted from Schimmer and Parker (22), and Barnes (26))

<i>Factor</i>	Glucocorticoid effect on gene transcription	<i>Comments</i>
Arachadonic Acid and metabolites (prostaglandins and leukotrienes)	Increased transcription of lipocortin 1	Inhibition via glucocorticoid induction of lipocortin that inhibits phospholipase A ₂ (macrophages, monocytes, fibroblasts)
Interleukin IL-10	Increased transcription	Anti-inflammatory cytokine secreted by macrophages inhibits transcription of many pro-inflammatory cytokines, chemokines and inflammatory enzymes
Cytokines: IL-1, IL-2, IL-3, IL-4, IL-5, IL-6, IL-11, 12, IL-13, TNF- α , GM-CSF	Decreased transcription	Cytokines exert multiple pro-inflammatory effects production and release blocked by glucocorticoids (macrophages, monocytes, lymphocytes, endothelial cells)
Interleukin (IL)-receptor antagonist	Increased transcription	Cytokine that block the binding of IL-1 to its receptors, glucocorticoids increase synthesis
Chemokines: IL-8, RANTES, MIP-1 α , MCP-1, MCP-3, -4, cotaxin	Decreased transcription	Chemokines attract inflammatory cells to site of inflammation, synthesis inhibited by glucocorticoids
Inducible form of Nitric Oxide Synthase (iNOS)	Decreased transcription	Nitric Oxide synthase may increase blood flow and plasma exudation and amplify inflammatory response, potently inhibited by glucocorticoids
Cyclo-oxygenase 2 (COX-2)	Decreased transcription	Glucocorticoids inhibit the induction of the gene coding for COX-2 in monocytes and macrophages
Tachykinins	Repression of the preprotachykinin-A gene, reduced expression of tachykinin receptors, increased expression of neutral endopeptidase which degrades tachykinins	Glucocorticoids may inhibit neurogenic inflammation by decreasing tachykinins which may amplify inflammatory responses
Bradykinin	Increased transcription of Kinase II or angiotensin converting enzyme (ACE)	Glucocorticoids suppress bradykinin levels by increased degradation of bradykinin via induction of ACE synthesis. Bradykinin produces vasodilation, increased vascular permeability, nociceptor activation, and leukocyte attraction

plasma exudation, thus amplifying the inflammatory response. Glucocorticoids produce a potent inhibition of nitric oxide synthase, leading to a decrease in inflammation (26). Glucocorticoids may also inhibit neurogenic inflammation by inhibition of the release of neuropeptides (26).

In contrast to the multiple sites of action and multiple anti-inflammatory effects of glucocorticoids, the anti-inflammatory and analgesic effects of NSAID's are much more selective. NSAIDs are believed to act primarily via inhibition of the enzyme

cyclo-oxygenase, which converts arachadonic acid to prostaglandin endoperoxides. Glucocorticoids could therefore be presumed to have greater anti-inflammatory and possibly greater analgesic properties than the NSAIDs in pain conditions where multiple inflammatory mediators are present and contribute to the development of inflammation and pain.

Several studies have reported that glucocorticoids suppress postoperative edema in oral surgery patients (18, 31–33). It may be conjectured that in an endodontic pain model a reduction in periapical edema in

a relatively non-compliant area might lead to a reduction in pain (3).

Most of the effects mediated by glucocorticoids are not immediate since time is required for changes in gene expression and protein synthesis to occur; thus, steroid actions many only be apparent after several hours or even days after administration. This delayed onset of action has been shown in a study by Nobuhara et al. (34), where administration of systemic dexamethasone significantly reduced the numbers of PMN's in periapical tissue after endodontic over-instrumentation but not until 48 h postoperatively.

Glucocorticoids have been used in endodontics for their potent anti-inflammatory effects. They may have widespread effects on many organ systems but these effects are typically only seen at supraphysiological doses given over a long-term period, usually more than 2 weeks. It has been stated that 'A single dose of glucocorticoid, even a large one, is virtually without harmful effects, and a short course of therapy up to 1 week) in the absence of specific contraindications, is unlikely to be harmful' (22). This has been demonstrated in an *in vivo* study by Czerwinski et al. (35) who concluded that single large doses (2 mg/kg) of dexamethasone were essentially without harmful side-effects. This dosage is 10–25 times the amount advocated for endodontic pain attenuation.

Glucocorticoids are contraindicated in patients with systemic fungal infection and known hypersensitivity to the drug. Steroids should be used with caution in patients with ulcerative colitis, pyogenic infection, diverticulitis, peptic ulcer, renal insufficiency, hypertension, osteoporosis, pregnancy, diabetes mellitus, ocular herpes, acute psychosis and history of tuberculosis (36). Psychological disturbances can occur during glucocorticoid therapy. These reactions are reversible and range in severity from mild (euphoria, insomnia, or nervousness) to pronounced (manic-depressive or schizophrenic psychosis). The frequency and severity of adverse effects are correlated to the dose and duration of therapy (37). Drug interactions associated with the corticosteroids appear to be minimal. Certain drugs decrease blood levels of the steroid via increased metabolic clearance; these include phenobarbital, phenytoin, rifampin, and ephedrine. Short-term steroid use can produce a reversible suppression of endogenous cortisol production. Williamson et al. (38) have shown that this suppression is compensated for by adequate amounts of synthetic steroid and

therefore prevents manifestations of adrenal insufficiency. NSAIDs should not be used with steroids due to increased GI adverse effects.

The anti-inflammatory properties of glucocorticoids were first appreciated and utilized as an adjunct to endodontic therapy almost half a century ago (39–41). Glucocorticoids have been used as a pulp-capping agent (42), as an intracanal medicament either alone or in combination with antibiotics/antihistamines (13, 39, 40, 43, 44), and systemically (3, 4, 9, 14, 41, 45–50) as a means to decrease pain and inflammation in endodontic patients. The following section will critically evaluate this research and then make recommendations for the use of glucocorticoids in endodontics; these recommendations will include, indications, contraindications, case selection, agent, dosage, and route of administration.

Several studies have evaluated the intracanal administration of steroids in endodontic patients. Wolfsohn (39) in 1954 first reported on the use of a steroid as an intracanal medicament. His uncontrolled report included 79 cases of either acute serous or acute suppurative pulpitis. After instrumentation, 0.5 mL of hydrocortisone was placed into the canal(s) followed by a temporary filling. Patients reported their pain at 24, 48 and 72 h. The author concluded that the use of hydrocortisone resulted in the reduction and elimination of severe secondary inflammatory reactions in the periodontal membrane following treatment. Blitzer (40) recommended the use of TACT (terramycin, antihistamine, cortril (25 mg/cc hydrocortisone) and tetracycline) as an intracanal medicament in cases where polyantibiotic therapy had failed. He reported on 51 cases, of which only two were failures, and concluded that hydrocortisone aids materially in reducing inflammation in the periapical tissues.

Ehrmann (43) reported on the use of Ledermix (triamcinolone and dimethylchlorotetracycline in a water soluble cream) for pulp capping, exposures, and as an intracanal medicament in cases with pericementitis. He concluded that Ledermix stopped the pain associated with pericementitis. Langeland et al. (44) used Ledermix as an intracanal medicament in cases of continued postoperative pain after pulpal extirpation or canal instrumentation. They reported pain relief in these cases within minutes to a few hours after the placement of Ledermix. In a double-blind clinical study of 50 consecutive patients with vital pulps, another study compared the use of 0.1 cc/ca-

nal of dexamethasone (4 mg/cc) to sterile saline 0.1 cc/canal as an intracanal analgesic (51). After complete instrumentation, the intracanal medicament was placed in the canal(s) followed by a temporary filling. Patients recorded their preoperative pain levels as well as post treatment pain at 24, 48 and 72 h. The authors reported that the dexamethasone group had significantly less pain at 24 h when compared to placebo ($P < 0.05$). No postoperative infections were noted in either group.

Chance et al. (52) in a double-blind study compared the effect of intracanal meticortelone (prednisolone acetate 2.5%) vs. saline on post treatment pain in 280 patients. The preoperative pulpal and periapical diagnosis was recorded for each patient; however, pretreatment pain levels were not noted. After complete instrumentation, the intracanal solution was placed in the canal via three applications of a saturated paper point followed by a cotton pellet and temporary filling. Patients reported their pain at 24 h post treatment. The results indicate that the corticosteroid was effective in significantly reducing the incidence of pain in vital teeth when compared to saline ($P < 0.05$). There was no difference in pain incidence in necrotic teeth when comparing the two solutions.

Rogers et al. (13) compared the pain-reducing efficacy of dexamethasone and ketorolac when used as an intracanal medication, with oral ibuprofen and a placebo. Forty-eight patients were included in the study. Following instrumentation of the vital pulps, two groups received either 0.1 mL dexamethasone (4 mg/mL) or 0.1 mL ketorolac tromethamine (30 mg/mL) as an intracanal medicament. The other two groups received no intracanal medication and either ibuprofen (600 mg) or an oral placebo. Patients recorded their pain pretreatment and post treatment at 6, 12, 24 and 48 h after therapy initiation on a visual analog scale. At the 12-h period, both dexamethasone and ketorolac provided statistically better pain relief than placebo ($P < 0.05$). At the 24-h period, only ketorolac had better pain relief than placebo. There were no differences at 6 and 48 h. No differences were seen between groups in the amount of post-treatment pain medication required.

Negm (53) in a randomized, double-blind study determined the effect of a corticosteroid-antibiotic combination compared to placebo for the treatment of post treatment pain in vital teeth. A total of 480

patients with interappointment pain were included in this study. Previously instrumented teeth were reopened without anesthesia, and medicated with either Kenacomb (nystatin 100 000 units/g, neomycin 2.5 mg/g, gramicidin 0.25 mg/g, triamcinolone 1.0 mg/g in aqueous cream base) or placebo (aqueous cream) and coronally sealed with Cavit. Patients recorded pain as none, mild, moderate and severe at 1, 2, 4, 8, 12, and 24 h post medication. Results showed that the intracanal use of corticosteroid-antibiotic medication significantly reduced the mean pain score at all time periods when compared to placebo ($P < 0.001$).

Several other studies have evaluated the effects of systemically administered steroids for treating endodontic pain patients. The systemic administration of a corticosteroid to alleviate pain and inflammation in endodontic patients was first reported by Stewart & Chilton (41) in 1958. The authors reported on 107 patients who presented for endodontic treatment with severe infection and swelling or had a postoperative 'flare-up' (see article by R. Walton in this issue of *Endodontic Topics* for more information on flare-ups). After canal instrumentation and temporization, the patients received a combination of corticosteroid, antihistamine, and antibiotic to be taken orally. This combination included metreton (2.5 mg prednisone, 2 mg chlorophenpyridamine) 1 tablet TID for 2 days and penicillin 250 mg TID for 3 days. Conclusions were that the use of corticosteroid-antihistamine-antibiotic therapy before or after conservative endodontic therapy appeared to be very helpful in reducing acute symptoms.

Stewart (54) evaluated the effect of oral dexamethasone either alone or in combination with oral penicillin on endodontic post treatment inflammation. Teeth with vital or necrotic pulps were included. After endodontic instrumentation and temporization, patients were divided into four groups; a control group that received no medication, an antibiotic group that received phenethicillin 250 mg TID for 3 days, a steroid group that received dexamethasone 0.75 mg BID for 2 days, and an antibiotic/steroid group that received both phenethicillin and dexamethasone. In his summary, the author stated that 'dexamethasone is capable of minimizing postoperative inflammation and consequent edema and pain thus substantially reducing requirements for analgesics.'

In a randomized, prospective, double-blind, placebo controlled study by Marshall & Walton (3), the

effect of intramuscular injection of dexamethasone on post treatment endodontic pain was compared to placebo. After endodontic instrumentation and/or obturation, patients received an IM injection of 1.0 mL of dexamethasone (4 mg/mL) or 1.0 mL of sterile saline. Pain levels were recorded preoperatively and at 4, 24 and 48 h post treatment. Results indicated that dexamethasone significantly reduced pain incidence and severity at 4 h post treatment. At 24 h post treatment, patients who received the corticosteroid showed a trend towards less pain. Teeth with vital and necrotic pulps were included as well as retreatment cases. No antibiotics were taken by any patients and there were no post treatment infections reported. The amount of postoperative pain medication required was not recorded.

Krasner & Jackson (45), in a double-blind study, evaluated the effect of oral dexamethasone on post treatment endodontic pain. Fifty patients presenting for endodontic treatment were included in this study. Retreatment cases and patients presenting with purulent drainage or cellulitis were excluded. Teeth were instrumented and closed with no intracanal medication. Pre-treatment and 8 and 24 h post treatment pain levels were recorded on a 0 to 100 scale. Patients randomly received dexamethasone (0.75 mg/tablet) or placebo with instructions to take 3 tablets immediately and then 1 tablet every 3 h until bedtime for a total of 7 tablets. Results showed that patients receiving oral dexamethasone had significantly less pain at 8 and 24 h when compared to those receiving placebo ($P < 0.01$).

Glassman et al. (46) also evaluated the efficacy of oral dexamethasone on endodontic interappointment pain but with a much higher dosage of the corticosteroid. Forty patients with asymptomatic vital inflamed pulps were included in this study. After endodontic instrumentation and temporization, alternate patients were given either dexamethasone (4 mg/tablet) or placebo. Instructions were to take 1 tablet immediately and then 1 tablet at 4 and then 8 h post treatment for a total oral dose of 12 mg in the dexamethasone group. Patients were given a questionnaire to record pain on a visual analog pain scale at 8, 24, and 48 h post treatment. Results showed that patients receiving dexamethasone had a statistically significant reduction in pain at all post treatment time periods.

Liesinger et al. (4) in a double-blind, randomized, prospective, placebo controlled study evaluated the

effect of four different doses of dexamethasone on post treatment endodontic pain. All 106 patients included in the study presented with pretreatment pain. Endodontic instrumentation and/or obturation were performed after which patients received a randomized intraoral intramuscular injection of placebo (1 mL sterile saline), or one of four doses of dexamethasone (2 mg/mL, 4 mg/mL, 6 mg/mL, 8 mg/mL). The injection was given into either the masseter, internal pterygoid, or buccinator muscle. Preference was given to intraoral muscles anesthetized for treatment. Patients recorded their pretreatment pain levels on a 0–9 scale and post treatment pain levels at 4, 8, 24, 48 and 72 h. Type and amounts of pain medication taken was also recorded. No antibiotics were given at any time during this study and both vital and necrotic teeth were included for treatment. Results showed patients receiving dexamethasone had significantly less severe pain at 4 and 8 h postoperatively ($P < 0.05$), and took significantly less pain medication ($P < 0.05$) compared to placebo (mean of 1.98 tablets for dexamethasone vs. mean of 4.64 tablets for placebo). When evaluated on a mg/kg dosage basis, it was found that patients who received 0.07–0.09 mg/kg of dexamethasone IM had significantly less pain at 8 h and took significantly fewer pain medications when compared to placebo.

Kaufman et al. (47) were the first to evaluate the effect of an intraligamentary delivery of corticosteroid on endodontic post treatment pain. Forty-five patients presenting for endodontic treatment were randomly assigned to one of three experimental groups. Endodontic treatment was completed in one appointment on both vital and necrotic pulps, with and without periapical radiolucencies. After anesthesia was achieved but prior to endodontic treatment, patients in group 1 received 4–8 mg of Depo-medrol (slow-release methylprednisolone) via intraligamentary syringe. Single-rooted teeth received 4 mg, and multirrooted teeth 8 mg. Group 2 received PDL injection of mepivacaine 3% in a similar fashion to group 1. Group 3 received no PDL injection. Pretreatment pain levels were not reported. The patients were telephoned at 24 h and reported pain intensity on a 1–10 scale. The results showed a significant decrease in postoperative pain in the methylprednisolone group ($P < 0.05$) compared to the active and passive placebo groups. In another prospective, randomized, double-blind, placebo controlled study that contained 588 consecutive patients.

Torabinejad et al. (9), evaluated the effectiveness of various medications on postoperative pain following complete instrumentation. The preoperative pulpal and periapical diagnosis was recorded as well as preoperative pain levels on a 0–9 scale. After instrumentation, patients were given one of 10 different medications or combination of medications. These included non-steroidal anti-inflammatories, antibiotics, acetaminophen, steroid and a narcotic analgesic. One of these combinations was methylprednisolone 2 mg and penicillin 500 mg. Patients took one dose immediately then one dose every 6 h for the next 66 h for a total dose of 24 mg of methylprednisolone and 6 g of penicillin. Post treatment pain levels were recorded every 6 h for 72 h. Amongst their many findings, the authors reported that those patients who presented for treatment with moderate–severe pain and who received the steroid/antibiotic combination had significantly less pain at 6, 18 and 24 h when compared to the placebo group ($P < 0.05$). They found no significant post treatment pain differences between any of the test medications when compared to placebo in patients with no or mild pretreatment pain.

In a very elegant study, Gallatin et al. (48) evaluated pain reduction for untreated irreversible pulpitis using an intraosseous injection of methylprednisolone. Forty patients with a clinical diagnosis of irreversible pulpitis actively associated with moderate–severe pain participated in this prospective double-blind study. The involved tooth was anesthetized followed by an intraosseous injection of 1 mL methylprednisolone (Depo-Medrol 40 mg/mL) or 1 mL of saline. The blinded solutions were administered using the Stabident system (Fairfax Dental, Inc., Miami, FL, USA). No endodontic treatment was performed. Patients were given a 7-day pain diary as well as analgesic medication. Over the 7-day observation period, subjects receiving Depo-Medrol reported significantly less pain ($P < 0.05$) compared to placebo while taking significantly fewer analgesic medications ($P < 0.05$).

Bramy et al. (14) evaluated the intraosseous administration of corticosteroid for pain reduction of symptomatic teeth necrotic teeth. Thirty-eight patients with a clinical diagnosis of pulpal necrosis with associated periapical radiolucency participated in the study. All patients experienced moderate/severe pain at time of presentation with mild or no clinical swelling. After

endodontic treatment (complete debridement) patients in a double-blind fashion randomly received an intraosseous injection of either 1 mL methylprednisolone (Depo-Medrol 40 mg/mL) or 1 mL of sterile saline placebo. All subjects received ibuprofen and Tylenol #3™ and recorded their pain levels and any pain medications taken for 7 days postoperatively. The results showed that the steroid group had significantly less postoperative pain and took significantly less pain medication over 7 days ($P < 0.05$). No antibiotics were taken by patients at any time during the study.

In a follow-up study, Claffey et al. (49) evaluated pain reduction in symptomatic teeth with necrotic pulps using an oral dose regimen of methylprednisolone. The materials and methods were nearly identical to Bramy et al. except that no patient had clinical swelling and after the canal debridement, patients randomly received in a double-blind fashion either oral methylprednisolone (48 mg/day for 3 days) or a placebo control (lactose 48 mg/day for 3 days). All patients received ibuprofen and Tylenol #3 (tm) and a diary to record pain, percussion pain, swelling and number and type of pain medications taken. Clinical success was defined as any patient who experienced only mild to no pain, mild to no percussion pain, mild to no swelling and did not take any Tylenol #3. Again, no antibiotics were prescribed or taken during this study. The results showed that patients receiving oral methylprednisolone had significantly higher clinical success for the first 3 days after endodontic treatment ($P = 0.05$).

In critically evaluating the preceding studies for validity, it must be kept in mind that the most powerful conclusions are those generated from studies that are prospective, randomized, double-blind and placebo controlled. None of the endodontic reports on the use of corticosteroids published prior to 1984 meets these criteria and therefore the results should be considered anecdotal. Results from studies that used corticosteroids in combination with other agents such as an antibiotic and/or an antihistamine are difficult to interpret, as results ascribed to one of the agents may be the result of the combination. Equally difficult to interpret are results from studies using intracanal steroid as the means of delivery (13, 52, 53). The methodology in these studies doesn't account for how much and over what time period the intracanal medicament reaches the site of action, the periapical

tissues. Very small concentrations of the agent are placed into the canal(s) and assuming apical patency of variable size must pass through the apical foramen via a concentration gradient against a potential back pressure from periapical transudate or exudate. This would seem to leave those studies that administered corticosteroids in a systemic manner (intramuscular, intraosseous, oral) in a known dose without any other agents as the critical ones in evaluating the efficacy of steroids in the ability to decrease endodontic pain. Prior to interpreting these studies (3, 4, 13, 45–49) it is important to remember that endodontic treatment itself has a major effect on reducing post treatment pain regardless of analgesic intervention (Fig. 1). As stated by Hargreaves (19) ‘This reduction in post treatment pain, combined with variable levels of pre-operative pain, reduces the statistical power of endodontic clinical trials for detecting active analgesics over time in all patient groups (the so-called floor effect). This limitation is a problem in interpreting clinical studies in general and may explain why some endodontic clinical trials fail to detect analgesic treatment or only detect it in those patients with moderate/severe pain.’ This has been shown by Torabinejad et al. (9) and Rogers et al. (13) where various agents including corticosteroid significantly decreased post treatment pain but only in those patients who presented with at least moderate/severe pretreatment pain. It would therefore seem that systemic administration of corticosteroid as a method to decrease endodontic post treatment pain might be appropriate only for those patients who present with moderate/severe pain. Three independent studies (4, 14, 49) meet the criteria of being prospective, randomized, double-blind placebo controlled with no drug combinations and including only patients who presented with the required level of pretreatment pain. Importantly, these studies showed that systemic administration of corticosteroid not only significantly reduced post treatment pain at various times but also significantly reduced the amount of additional pain medication required.

Interestingly, the reports by Bramy et al. (14) and Claffey et al. (49) show significant pain relief for up to 7 days with the use of steroid, in contrast to Liesinger et al. (4) who found significant differences in pain reduction only in the first 8 h. It is possible these differences could be due to differences in doses of different corticosteroids or by different routes of ad-

ministration. This is probably not the case, as seen in Table 1 dexamethasone is approximately 5 times as potent as methylprednisolone and the 6–8 mg intramuscular doses used by Liesinger et al. (4) would be equivalent to 30–40 mg of methylprednisolone with 40 mg of intraosseous methylprednisolone being the dose used by Bramy et al. (14). It is possible to speculate that these differences therefore might be more related to the preoperative pulpal and periapical diagnosis. All of the patients in the studies by Bramy et al. and Claffey et al. (14, 49) presented with necrotic pulps, associated periapical radiolucencies, and either mild or no swelling. The majority of patients in the study by Liesinger et al. (4) presented with a diagnosis of irreversible pulpitis and acute apical periodontitis and those patients with necrotic pulps had no associated periapical radiolucencies. It seems plausible that corticosteroids may be more efficacious in attenuating pain associated with pulpal necrosis and associated radiolucencies compared to pain associated with irreversible pulpitis since these conditions are associated with more complex chronic inflammatory processes. Thus, the efficacy of steroids in endodontic pain patients could be related to variations in the periapical immunological/inflammatory dynamics of teeth with irreversibly inflamed vs. necrotic pulps.

Based on the work of Bramy et al. and Claffey et al. (14, 49), it also seems plausible that corticosteroids would have efficacy in those cases of endodontic flare-up that result after treatment of previously asymptomatic necrotic teeth with or without associated periapical radiolucencies. This premise has not been investigated and, with the low incidence of this type of flare-up (1), would require a multicenter study over a period of years to gather an adequate sample size.

Collectively, it appears from the studies reported (4, 14, 49) that the route of systemic administration of glucocorticoids is not a determinant in their efficacy and that when given in equivalent dosages, agents such as dexamethasone and methylprednisolone are interchangeable. It would seem that if a systemic steroid is to be administered, an intraoral IM injection or an intraosseous injection would be preferable over an extraoral IM injection as the practitioner is familiar with intraoral and intraosseous injections and the site of injection is already anesthetized. Intraoral injection of steroid would be preferable to a prescription for glucocorticoid as no assumption about patient com-

pliance is required. A dose of 6–8 mg of dexamethasone or 40 mg of methylprednisolone appears from the literature to be appropriate. If an oral route is chosen 48 mg methylprednisolone/day for 3 days and by extrapolation 10–12 mg dexamethasone/day for 3 days should provide significant post treatment pain relief.

It has been stated (38, 41, 50, 55) that antibiotics must be given in conjunction with steroids to prevent an infection secondary to a decrease in the inflammatory response. The implication is that suppression of inflammation also means a decrease in local defenses permitting unchecked proliferation of pathogenic microorganisms. None of the studies published since 1984 would support this premise, including those cases with a diagnosis of pulpal necrosis with periapical radiolucency (14, 49) where the potential for dissemination of an infectious process might be expected. Antibiotics were not given or needed at any time during these studies nor were the steroids associated with any increase in infection rate compared to the control group. It can therefore be concluded that antibiotics are not routinely required or recommended in conjunction with corticosteroids for the management of endodontic post treatment pain in the otherwise healthy patient. Several excellent reviews on antibiotics and endodontic pain are available (56), including the article by A. Fouad in this issue of *Endodontic Topics*.

In conclusion, it appears after a careful review of the literature that the administration of systemic steroids is efficacious as an *adjunct to* but not replacement for *appropriate endodontic treatment* in the attenuation of endodontic post treatment pain. Systemic steroids are also highly effective in those patients who present for treatment with moderate/severe pain and a clinical diagnosis of pulpal necrosis with associated periapical radiolucency.

References

- Walton RE, Fouad A. Endodontic flare-ups. A prospective study of incidence and related factors. *J Endod* 1992; **18**: 172–177.
- Genet JM, Hart AAM, Wesselink PR, Thoden Van Helzen SK. Preoperative and operative factors associated with pain after the first endodontic visit. *Int Endod J* 1987; **20**: 53–64.
- Marshall JG, Walton RE. The effect of intramuscular injection of steroid on post treatment pain. *J Endod* 1984; **10**: 584–588.
- Liesinger A, Marshall FJ, Marshall JG. Effect of variable doses of dexamethasone on post treatment endodontic pain. *J Endod* 1993; **19**: 35–39.
- Marshall JG, Liesinger AW. Factors associated with endodontic post treatment pain. *J Endod* 1993; **19**: 573–575.
- Hasselgren G, Reit C. Emergency pulpotomy. Pain relieving effect with and without the use of sedative dressings. *J Endod* 1989; **15**: 254–256.
- Oguntebi BR, DeShepper EJ, Taylor TS, White CL, Pink FE. Postoperative pain incidence related to the type of emergency treatment of symptomatic pulpitis. *Oral Surg Oral Med Oral Pathol* 1992; **73**: 479–483.
- Penniston SG, Hargreaves KM. Evaluation of periapical injection of Ketorolac for management of endodontic pain. *J Endod* 1996; **22**: 55–59.
- Torabinejad M, Cymerman JJ, Frankson M, Lemon RR, Maggio JD, Schilder H. Effectiveness of various medications on postoperative pain following complete instrumentation. *J Endod* 1994; **20**: 345–354.
- Moos HL, Bramwell JD, Roahen JO. A comparison of pulpectomy alone versus pulpectomy with trephination for the relief of pain. *J Endod* 1996; **22**: 422–425.
- Doroshak A, Bowles W, Hargreaves K. Evaluation of the combination of flurbiprofen and tramadol for management of endodontic pain. *J Endod* 1999; **25**: 381–384.
- Rosenberg PA, Babick PJ, Schertzer L, Leung A. The effect of occlusal reduction on pain after endodontic instrumentation. *J Endod* 1998; **24**: 492–496.
- Rogers MJ, Johnson BR, Remeikis NA, BeGole EA. Comparison of effect of intracanal use of ketorolac tromethamine and dexamethasone with oral ibuprofen on post treatment endodontic pain. *J Endod* 1999; **25**: 381–384.
- Bramy E, Reader A, Beck M, Weaver J. The intraosseous injection of Depo-medrol on postoperative endodontic pain in symptomatic, necrotic teeth. *J Endod* 1999; **25**: 289 (Abstract OR 29).
- Nist E, Reader A, Beck M. Effect of apical trephination on postoperative pain and swelling in symptomatic necrotic teeth. *J Endod* 2001; **27**: 415–420.
- Cooper SA, Precheur H, Rauch D, Rosenheck A, Ladov M, Engel J. Evaluation of oxycodone and acetaminophen in treatment of postoperative dental pain. *Oral Surg Oral Med Oral Pathol* 1980; **50**: 496–501.
- Forbes JA, Bowser MW, Calderazzo JP, Foor VM. An evaluation of the analgesic efficacy of three opioid-analgesic combinations in postoperative oral surgery pain. *J Oral Surg* 1981; **39**: 108–112.
- Troullos ES, Hargreaves KM, Butler DP, Dionne RA. Comparison of nonsteroidal anti-inflammatory drugs, ibuprofen and flurbiprofen with methylprednisolone and placebo for acute pain, swelling, and trismus. *J Oral Maxillofac Surg* 1990; **48**: 945–952.
- Hargreaves KM, Seltzer S. Pharmacologic control of dental pain. In: Hargreaves KM, Goodis H, eds. *Seltzer and Bender's dental pulp*. Chicago: Quintessence Publications, 2002.
- Hargreaves KM, Baumgartner JC. Endodontic Therapeutics. In: Walton R, Torabinejad M, eds. *Principles and practice of endodontics*. Philadelphia: WB Saunders, pp 530–544, 2002.
- Byers MR, Taylor PE, Khayat BG, Kimberly CL. Effects

- of injury and inflammation on pulpal and periapical nerves. *J Endod* 1990; **16**: 78–84.
22. Schimmer BP, Parker KL. Adrenocorticotropic hormone. Adrenocortical steroids and their synthetic analogs; Inhibitors of the synthesis and actions of adrenocortical hormones. In: Hardman JG, Limbird LE, eds. *Goodman and Gilman's the pharmacological basis of therapeutics*. New York: McGraw-Hill, 1996.
 23. Holland GR. Steroids reduce the periapical inflammatory and neural changes after pulpectomy. *J Endod* 1996; **22**: 455–458.
 24. Smith RG, Patterson SS, El-Kafrawy AH. Histologic study of the effects of hydrocortisone on the apical periodontium of dogs. *J Endod* 1976; **2**: 376–380.
 25. Di Rosa M, Calignano A, Carnuccio R, Ialenti A, Sautebin L. Multiple control of inflammation by glucocorticoids. *Agents Actions* 1985; **17**: 284–289.
 26. Barnes PJ. Anti-inflammatory actions of glucocorticoids: molecular mechanisms. *Clin Sci* 1998; **94**: 557–572.
 27. Isett J, Gallatin E, Reader A, Beck M, Padgett D. Effect of intraosseous injection of depo-medrol on pulpal concentrations of PGE2 and IL-8 in untreated irreversible pulpitis. *J Endod* 2000; **26**: 542 (Abstract) OR 28.
 28. Fouad AF. Molecular mediators of pulpal inflammation. In: Hargreaves KM, Goodis H, eds. *Seltzer and Bender's dental pulp*. Chicago: Quintessence Publications, 2002.
 29. Babe KS, Serafin WE. Histamine, Bradykinin, and their antagonists. In: Hardman JG, Limbird LE, eds. *Goodman and Gilman's the pharmacological basis of therapeutics*. New York: McGraw-Hill, 1996.
 30. Hargreaves KM, Costello A. Glucocorticoids suppress release of immunoreactive bradykinin from inflamed tissue as evaluated by microdialysis probes. *Clin Pharmacol Ther* 1990; **48**: 168–178.
 31. Pedersen A. Decadron phosphate in the relief of complaints after third molar surgery. *Int J Oral Surg* 1985; **14**: 235.
 32. Sisk A, Bonnington GJ. Evaluation of methylprednisolone and flurbiprofen for inhibition of the postoperative inflammatory response. *Oral Surg Oral Med Oral Pathol* 1985; **60**: 137.
 33. Skelbred P, Lokken P. Postoperative pain and inflammatory reaction reduced by injection of a corticosteroid. A controlled trial in bilateral oral surgery. *Eur J Clin Pharmacol* 1982; **21**: 391.
 34. Nobuhara WK, Carnes DL, Giles JA. Anti-inflammatory effects of dexamethasone on periapical tissues following endodontic over-instrumentation. *J Endod* 1993; **19**: 501–507.
 35. Czerwinski AW, Czerwinski AB, Whitsett TL, Clark ML. Effects of a single large intravenous injection of dexamethasone. *Clin Pharmacol Ther* 1972; **13**: 638–642.
 36. Anonymous. *Physicians Desk Reference*, 55th edn. Montvale NJ: Medical Economics Co. Inc., 2001: 2595.
 37. Trammel CL. Anti-inflammatory drugs. In: Yagiela JA, Neidle EA, Dowd FJ, eds. *Pharmacology and therapeutics for dentistry*. St. Louis: Mosby, 1998.
 38. Williamson LW, Lorson EL, Osbon DB. Hypothalamic-pituitary-adrenal suppression after short-term dexamethasone therapy for oral surgical procedures. *J Oral Surg* 1980; **38**: 20–38.
 39. Wolfson BC. The role of hydrocortisone in the control of apical periodontitis. *Oral Surg Oral Med Oral Pathol* 1954; **7**: 314–321.
 40. Blitzer MH. Root canal therapy. Use of a combination of antibacterial agents, hydrocortisone and hyaluronidase. *NY State Dent J* 1956; **22**: 503–508.
 41. Stewart GG, Chilton NW. Role of antihistamines and corticosteroids in endodontic practice. *Oral Surg Oral Med Oral Pathol* 1958; **11**: 433–440.
 42. Fry AE, Watkins RF, Phatak NM. Topical use of corticosteroids for the relief of pain sensitivity of dentine and pulp. *Oral Surg Oral Med Oral Pathol* 1960; **13**: 594–597.
 43. Ehrman GH. The effect of triamcinalone with tetracycline on the dental pulp and apical periodontium. *J Prosthet Dent* 1965; **15**: 149–152.
 44. Langeland K, Langeland LK, Anderson DM. Corticosteroids in dentistry. *Int Dent J* 1977; **27**: 217–251.
 45. Krasner P, Jackson E. Management of post-treatment endodontic pain with oral dexamethasone: a double blind study. *Oral Surg Oral Med Oral Pathol* 1986; **62**: 187–190.
 46. Glassman G, Krasner P, Morse DR, Rankow H, Lang J, Furst ML. A prospective randomized double-blind trial on efficacy of dexamethasone for endodontic interappointment pain in teeth with asymptomatic inflamed pulps. *Oral Surg Oral Med Oral Pathol* 1989; **67**: 96–100.
 47. Kaufman E, Helling I, Rotstein I, Friedman S, Sion A, Moz C, Stabholtz A. Intra-ligamentary injection of slow-release methylprednisolone for the prevention of pain after endodontic treatment. *Oral Surg Oral Med Oral Pathol* 1994; **77**: 651–654.
 48. Gallatin E, Reader A, Nist R, Beck M. Pain reduction in untreated irreversible pulpitis using an intraosseus injection of depo-medrol. *J Endod* 2000; **26**: 633–638.
 49. Claffey D, Reader A, Beck M, Weaver J. Pain reduction in symptomatic, necrotic teeth using an oral dose regimen of methylprednisolone. *J Endod* 2001; **27**: 223 (Abstract OR 34).
 50. Klotz MD, Gerstein H, Bahn AN. Bacteremia after topical use of prednisolone in infected pulps. *J Am Dent Assoc* 1965; **71**: 871–875.
 51. Moskow A, Morse DR, Krasner P, Furst ML. Intracanal use of a corticosteroid solution as an endodontic anodyne. *Oral Surg Oral Med Oral Pathol* 1984; **58**: 600–604.
 52. Chance K, Lin L, Shoulin F, Skribner J. Clinical trial of intracanal corticosteroid in root canal therapy. *J Endod* 1987; **13**: 466–468.
 53. Negm MM. Intracanal use of a corticosteroid-antibiotic compound for the management of post treatment endodontic pain. *Oral Surg Oral Med Oral Pathol Oral Radiol Endod* 2001; **92**: 435–439.
 54. Stewart G. Combined use of an antibiotic and a corticosteroid for postoperative sequelae in endodontic practice. *J Dent Med* 1962; **17**: 142–146.
 55. Sinkford JC, Harris SC. The case against topical use of adrenocorticosteroids in dentistry. *J Am Dent Assoc* 1964; **68**: 765–767.
 56. Baumgartner JC. Antibiotics in endodontic therapy. In: Newman MG, van Winkelhoff AJ, eds. *Antibiotic and antimicrobial use in dental practice*. Chicago: Quintessence Publications, 2001.